

By L. Ronconi and M. Galli

***MonaLisa Touch*®: The Latest Frontier in the Treatment of Vaginal Atrophy**



The Code of Excellence

*A special thanks to Prof. Alberto Calligaro
for his invaluable dedication and support.*

Lara Ronconi
Biomedical Electronic Engineer
Medical Branch Supervisor
DEKA Company

Scientific Committee



Alberto Calligaro

Professor of Histology and Embryology of the English Degree Course in Medicine and Surgery at the University of Pavia. Past Dean of the Faculty of Medicine and Surgery of the same University, he is working in research activity at the Histology and Embryology Unit of the Department of Public Health, Neurosciences, Experimental and Forensic Medicine.



Massimo Candiani

Associated Professor of Obstetrics and Gynaecology at the University *Vita e Salute San Raffaele* of Milan, Faculty of Medicine and Surgery of Milan. Director of the Department for Motherhood and Childcare at San Raffaele Hospital.

Director of the Teaching Hospital and of the Complex Operative Unit of Obstetrics and Gynaecology at San Raffaele Hospital.



Mauro Galli

Doctor of Physics, with a PhD in Laser Physics.

Manager of the International Trade and Marketing Department of DEKA Company. Member of the steering committee of many companies of the EI.En. group of which DEKA is also a member.



Rossella Nappi

Associated Professor at the Section of Obstetrics and Gynaecology, Department of Clinical-Surgical, Diagnostic and Pediatric Sciences of the University of Pavia.

She works as a gynaecologist, endocrinologist and sex counsellor at the Research Centre for Medically Assisted Reproduction and Outpatient Clinics for Endocrinology, Gynaecology & Menopause, Obstetrics and Gynaecology Clinic of the IRCCS *Fondazione San Matteo* of Pavia.



Stefano Salvatore

Coordinator of the Urogynaecology Functional Unit – IRCCS *San Raffaele*, Milan. Contract Professor at the University *Vita e Salute San Raffaele* of Milan. Visiting Professor at the Imperial College St Mary's Hospital, University of London, UK. Member of the Scientific Committee of the International Urogynaecological Association. Vice-president of the European Urogynaecological Association.



Nicola Zerbinati

Dermatologist and Full Professor of the Degree Course in Dermatology and Venereology at the University of Insubria. Administrator of the CMP (Multi-specialty Medical Centre). Scientific Coordinator at ICAM (USA International Consultant in Aesthetic Medicine). Scientific Coordinator and Professor at IUL (International Union of Lipoplasty). Scientific Coordinator at IACG (International Academy of Cosmetic Gynaecology).

INDEX

INDEX	8
FOREWORD	12
Chapter 1	14
Vaginal Atrophy: Changes that Affect the Quality of Life	
1.1 INTRODUCTION	14
1.2 MENOPAUSE	16
1.2.1 Terminology and Definitions	16
1.2.2 Onset, Duration, Symptoms	17
1.3 VAGINAL ATROPHY	18
1.3.1 Alteration of the Epithelium of the Vaginal Mucosa	20
1.3.2 Vaginal Dryness	21
1.3.3 Decrease of Vaginal Lactobacilli and Increase of Vaginal pH Level	22
1.3.4 Treatments and Therapies	23
1.3.4.1 Non-Hormonal Therapies, Lubrication and Rehydration Treatments	25
1.3.4.2 Phytoestrogen-Based Preparations	26
1.3.4.3 Hormone Replacement Therapy	27
1.3.4.4 Tibolone	32
1.3.4.5 Local or Trans-Dermal Oestrogen Therapy	32
1.4 CONCLUSIONS	35
1.5 REFERENCES	35

Laser: the Light in Medicine

2.1	PREFACE	37
2.2	HISTORICAL OVERVIEW	37
2.3	PRINCIPLES OF OPERATION	38
2.4	CHARACTERISTICS OF THE LASER BEAM	40
2.5	TYPES OF LASERS	41
2.5.1	CO ₂ Laser	43
2.6	INTERACTION BETWEEN LASER AND BIOLOGICAL TISSUES	44
2.6.1	The Optical Properties of Biological Tissues	46
2.7	OVERVIEW ON THE USE OF LASER IN DERMATOLOGY	48
2.7.1	CO ₂ Laser in Dermatology	50
2.7.2	Neodymium Laser (Nd:YAG) in Dermatology	51
2.7.3	Alexandrite Laser in Dermatology	52
2.7.4	Dye Laser in Dermatology	52
2.7.5	Erbium Laser (Er:YAG) in Dermatology	53
2.8	OVERVIEW ON THE USE OF LASER IN OTHER MEDICAL FIELDS	53
2.8.1	Ophthalmology	53
2.8.2	Gynaecology	54
2.8.3	Otolaryngology	54
2.8.4	Urology	55
2.8.5	Dentistry	56
2.8.6	Oncology	57
2.8.7	Treatment of Arrhythmia	58
2.8.8	Biostimulation	58
2.9	OVERVIEW ON THE USE OF LASER FOR ART CONSERVATION	58
2.10	REFERENCES	59

MonaLisa Touch®: the First Laser-Assisted Technology for the Treatment of Vaginal Atrophy

3.1	INTRODUCTION	61
3.2	DEKA AND THE CO ₂ LASER	62
3.2.1	<i>DOT Therapy</i> : the Innovative Micro-Ablative Skin Rejuvenation Treatment	63
3.2.1.1	SmartPulse: Pulsed Emission Technology	66
3.2.1.2	SmartStack Function	67
3.3	FROM SKIN REJUVENATION TO VAGINAL REJUVENATION	68
3.3.1	Skin Versus Vaginal Mucosa	69
3.4	FROM CLINICAL INVESTIGATION TO THE NEED FOR AN ULTRASTRUCTURAL IN-DEPTH ANALYSIS	75
3.5	MICROSCOPICAL AND ULTRASTRUCTURAL OBSERVATIONS ON THE VAGINAL MUCOSA AFTER A CO ₂ FRACTIONAL LASER TREATMENT	77
3.5.1	Polarized Light Microscopy	79
3.5.2	Transmission Electron Microscopy	81
3.5.3	Discussion	91

3.6	PRACTICAL EFFECTS ON VAGINAL ATROPHY-RELATED SYMPTOMS	92
3.7	CO ₂ LASER IN VAGINAL ATROPHY TREATMENT	95
3.7.1	Evaluation of Clinical Results	98
3.7.2	Evaluation of Histological Results (both Microscopical and Ultrastructural Examinations)	101
3.8	MONALISA TOUCH®: A TECHNIQUE IN CONSTANT EVOLUTION	108
3.8.1	Conclusions	111
3.9	REFERENCES	111

APPENDIX A 113

Complete Before & After Histological Results

APPENDIX B 120

MonaLisa Touch® Peer-Reviewed Scientific Publications

APPENDIX C 139

MonaLisa Touch® White Papers

FOREWORD

The purpose of this publication is to present a new and innovative treatment for Vaginal Atrophy, a widespread condition among female population, especially in menopause.

Like any revolutionary idea, this method called *MonaLisa Touch*®, must be presented and explained to all people involved, namely healthcare professionals, media and patients. It is easy to understand that the language used in a publication should vary depending on the reader. Given the need to produce a single introductory document destined to a varied public, we have tried and found balance between “clarity” and “accuracy”, using the simplest possible language to simplify technical concepts. In case we did not always succeed, we have provided three links where readers can find more specific information:

1. www.monalisatouch.com – DOCTOR’s section
2. www.dekalaser.com – APPLICATIONS – V²LR

Both websites are addressed to healthcare professionals.

The first website is exclusively dedicated to *MonaLisa Touch*® with in-depth explanations, the updated bibliography and all the news in regard to this procedure.

The second one is the DEKA official website, where the *MonaLisa Touch*® treatment is explained within the wider context of Vulvo-Vaginal Laser Reshaping (V²LR): a new field of application in female urogenital apparatus with treatments that improve the aesthetic aspect and allow for the prevention and care of many problems occurring during menopause. The DEKA website for healthcare professionals contains detailed descriptions of available laser systems performing *MonaLisa Touch*® procedure.

3. www.monalisatouch.com – PATIENT’s section

This website is addressed to media and patients that delivers clear and simple sections on the new method *MonaLisa Touch*®, including related videos and publications, and the possibility to ask experts to answer any questions on the subject matter.

The book is divided into three different chapters. Key features include:

- The first chapter focuses on Vaginal Atrophy in order to understand its nature, symptoms and related problems. It also provides information on treatment options currently available. The purpose of this chapter is to get a clearer understanding of the problem we intend to solve with the *MonaLisa Touch*® treatment.
- The second chapter deals with laser technology. Indeed, the *MonaLisa Touch*® method is based on the use of a special CO₂ fractional laser, with dedicated pulse. Therefore, we thought that it would be interesting to provide some insight on this fascinating tool that is now extensively used in medicine as well as other fields.
- Finally, the third chapter presents the *MonaLisa Touch*® treatment: what it is, how it works, and updated results of clinical and histological studies. Undoubtedly, the understanding of histological images is not as immediate for non-experts. However, we have tried, as simply and clearly as possible, to explain the conclusions drawn from the histological results achieved, leaving more in-depth investigations to scientific publications.

Chapter 1

Vaginal Atrophy: Changes that Affect the Quality of Life

1.1 INTRODUCTION

The aim of this chapter is to provide information on the problems associated with vaginal atrophy, a very common condition in female population, especially during menopause. However, it appears to be relatively unknown to, and ignored by, doctors and patients.

Before dealing with this topic from a medical viewpoint, it might be useful to give an overview of the current social and cultural background in which European and North-American menopausal women live. First of all, we must better understand women that are in their fifties.

At the beginning of the 1900s, women's life expectancy coincided with the end of their childbearing years and even those who lived long after menopause experienced a decline both in their biological functions and personal relationships which alienated them from society.

Nowadays more than 95% of women reach menopause with a life expectancy, in the case of a 65 year-old, of 20 years^[1].

Women between the ages of 45 and 55 account for 10% of the population in Western countries^[2]. Naturally they are all different from one another, and yet share features of women who followed a similar path.

These are the women who entered the labour market in such a way as it has never happened to previous generations, above all women with high school diplomas and university

degrees. These are the women who have been able to enjoy significant changes such as the possibility of using contraception, divorce rights, to undergo an abortion, equal opportunities in the labour market and new laws governing family life.

The women of this generation have played an active role, taking centre stage in society and developing at the same time, a strong ability for self-criticism which was unknown to previous generations. This is, therefore, a generation of strong women that virtually have more tools to face the second part of their life; women who want to change and who are not resigned. This is still an active generation, partly because it is their calling and also because of the new responsibilities they have to undertake. Indeed, these women are the so-called 'sandwich generation' who care for their ageing parents and at the same time support their children. Many women between 45 and 55 years of age have at least one child who is dependent on them and their ageing parents need more care, help and assistance^[3]. Some of them also have grandchildren to take care of in order to allow their own daughters or their daughters-in-law to keep working. They often work and if they have a career in this stage of their life, they have to work even harder to make sure they are not easily replaced by the younger generation.

Finally, this 50-year old women generation is aware that they still have many years to live which are not residual or marginal years, but years that have to be lived to the fullest. Being aware that life expectancy after menopause is on average more than 30 years, it is absolutely crucial to focus on the needs of post-menopausal women. Society, institutions and the media are also more aware of these needs. That is why the health and quality of life of menopausal women are issues of growing concern.

1.2 MENOPAUSE

1.2.1 Terminology and Definitions

According to the World Health Organization (WHO), *natural menopause* is the permanent end of menses (amenorrhoea) that results from the loss of ovarian function, the diagnosis of which is reached retrospectively after 12 consecutive months of amenorrhoea that has no other physiological or pathological cause.

The age of menopause changes from woman to woman, but the average age is approximately 50 years worldwide.

Premature or early menopause is menopause that occurs before the age of 40 (WHO) and can be either natural or induced. The symptoms associated with it are those caused by decreased oestrogen levels.

Induced menopause is the end of menses following the surgical removal of one or both ovaries (with or without hysterectomy, which is the removal of the uterus) or drug-induced suppression of the ovarian function (chemotherapy, radiations, anti-cancer drugs such as Tamoxifen) (WHO).

The term *post-menopause* refers to the period that follows the last menses, regardless of whether menopause is natural or induced (WHO).

The term *perimenopause* refers to the period preceding menopause up to the first year after the last menstrual period (WHO).

To the list of definitions established and recognized at international level by the WHO in 1990 the *International Menopause Society* (IMS) added in 1999, the term *climacteric*, which defines the phase in a woman's life that precedes and follows, for a variable period of time,

the transition from childbearing to non-childbearing years, therefore including *perimenopause* and encompassing a longer period both before and after *perimenopause*.

1.2.2 Onset, Duration, Symptoms

Menopause is associated with numerous changes that virtually involve all the organs and apparatuses of the female body.

The alterations of the endocrine system that characterize perimenopause generally result in a change in the frequency and amount of menstrual bleeding. Approximately 90% of women before menopause experience menstrual disorders that can last from 4 to 8 years^[4].

After the last menstrual period, the second most frequent symptoms that follow menstrual irregularity in perimenopause are *vasomotor symptoms*, which are typical of decreased oestrogen levels (hot flushes, night sweats) and associated sleep disorders. They are also considered short-term symptoms as they generally disappear when oestrogen production stops. It is estimated that 85% of women experience vasomotor symptoms^[4]. Later in the post-menopausal phase other symptoms can also appear, such as urogenital disorders (irritation of the vagina with itching and burning pain, dryness and dyspareunia that are the result of vulvo-vaginal atrophy; urination disorders caused by urethral atrophy), which are regarded as medium term symptoms that can worsen over time, unlike vasomotor symptoms which conversely tend to completely disappear.

1.3 VAGINAL ATROPHY

The loss of oestrogen production in the ovaries is associated with the onset of vaginal atrophy. The genital tract is indeed particularly sensitive to a decline in oestrogen levels and approximately half of post-menopausal women experience the typical symptoms of vaginal atrophy that deeply affect sexual function and the quality of their life.

While hot flushes and night sweats naturally disappear overtime, the symptoms associated with vaginal and urethral atrophy often get worse and, in most cases, require targeted treatment.

The clinical manifestation of vaginal atrophy generally occurs 4-5 years after menopause and 25-50% of post-menopausal women present with objective changes as well as individual symptoms^[5]. The patients do not always inform their physician about the onset of these symptoms. Therefore, the aforesaid incidence percentage is undoubtedly underestimated.

Vaginal atrophy can occur both as a consequence of natural menopause and of induced menopause, following the removal of the ovaries, as well as of medical conditions that require pelvic radiation therapy or chemotherapy, with subsequent alteration of the ovarian function.

The vaginal health of European post-menopausal women (between 45 and 59 years of age) has been studied within the framework of a European large-scale survey^[6] conducted on 4201 women with a view to gathering information on the ideas, perceptions and attitudes women adopt towards menopause and, more generally, towards the treatment options available for menopause symptoms. The survey revealed that European women should receive more information on the implications that vaginal atrophy has on the quality of their life.

A survey conducted in North America shows that, notwithstanding the prevalence and diversification of symptoms associated with urogenital atrophy, only 25% of women that experience these symptoms inform their attending physician of these problems and 70% of women said that their physician rarely or never asks them about problems such as vaginal dryness^[7]. On the other hand, it would seem that patients and doctors tend to ascribe these symptoms to the natural and inevitable ageing process. This study clearly shows that while women are well aware of the relationship between hot flushes and the decrease in oestrogen levels, they do not associate the latter with vaginal disorders.

Data concerning vaginal problems in post-menopausal women in other parts of the world are underestimated. It is well known that in many Asian countries, such as India and the Middle East, psychological factors, cultural and religious taboos surrounding sexual life and other related topics, prevent women, mostly those from the lowest socio-economic classes, from talking about vaginal dryness and sex-related topics with healthcare professionals, even in the event of sexual dysfunction. However, if on the one hand most of these women are reticent about their sexual problems, at the same time they feel relieved if their doctor starts to talk about it and offers help^[5].

The situation of women in Sub-Saharan Africa is totally different. Their life expectancy at birth is only 55 years. If we take into account the spread of HIV/AIDS and other healthcare problems, we can easily understand why vaginal atrophy is not a healthcare priority in these countries^[5].

In South America there is a very negative cultural prejudice against menopause which is associated not only with ageing, but also with the loss of femininity. Surveys show

that vaginal atrophy is also a very significant feature of menopause symptoms^{[8],[9]} which alters the sexual function and affects the quality of life.

The decline in oestrogen levels associated with menopause is closely linked to:

- Morphological alterations of the epithelium of the vaginal mucosa;
- Reduction of blood flow and of vaginal secretion (vaginal dryness);
- Decrease of vaginal lactobacilli and increase of vaginal pH levels.

It is necessary to examine all of these changes more closely so as to get a better understanding of this problem.

1.3.1 Alteration of the Epithelium of the Vaginal Mucosa

The epithelium of the vaginal mucosa has a very important function since it also protects the mucosa against mechanical friction during sexual intercourse.

When oestrogen levels start declining, the epithelium gets thinner and becomes more susceptible to trauma (Figure 1.1).

The reduction of collagen in the connective tissue of the vaginal mucosa, whose role is to support the epithelium both structurally and functionally, causes the loss of the vaginal rugosity.

The thinning of the epithelium and loss of vaginal rugae generally occur 2-3 years after the onset of menopause^[5].

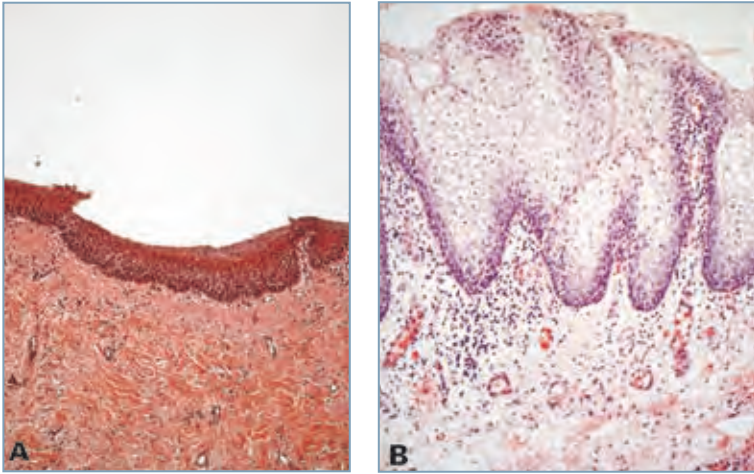


Figure 1.1 – Histological preparation of the vaginal mucosa stained with haematoxylin and eosin (H&E). (A): Post-menopausal vaginal mucosa with atrophy caused by decreased oestrogen levels with reduced presence of vessels and a significantly thinner epithelium with lack of glycogen. (B): Vaginal mucosa in reproductive age; the mucosa is well supplied with vessels and the epithelium consists of a larger number of cell layers, particularly rich in glycogen. [Courtesy of Prof. A. Calligaro University of Pavia].

1.3.2 Vaginal Dryness

Vaginal atrophy is one of the main factors that influence sexual function with significant effects on the quality of a woman's life.

It is quite easy to understand how important vaginal health is for sexual health. Oestrogens modulate the hemodynamic processes of sexual response; therefore, due to reduced oestrogen levels, menopausal women frequently present with vaginal dryness, and if sexually active, they can also experience disorders such as painful sexual intercourse (dyspareunia).

During sexual activity women can experience altered genital sensations, vasocongestion and lubrication, that in turn can cause other symptoms such as low sexual desire, low arousal, lack of orgasm and consequently reduced sexual fulfilment. Also, the health of the urinary

tract is closely linked to vaginal symptoms, above all in the absence of oestrogens.

Urinary tract symptoms, such as frequent urination mostly at night (nocturia), urinary urgency, painful urination (dysuria), urinary incontinence and post-coital infections are more common when there is also a certain degree of vaginal atrophy.

Therefore, even if vaginal dryness in menopausal women is not necessarily associated with sexual activity, sexually active women are those who most frequently report this problem precisely because of the pain experienced during sexual intercourse.

1.3.3 Decrease of Vaginal Lactobacilli and Increase of Vaginal pH Level

The vagina is colonised by a variety of bacteria that form the vaginal flora which creates a protective barrier that acts against the proliferation of different infections. Among the bacteria that comprise the vaginal flora the presence of Lactobacilli is very important, because they produce lactic acid and maintain an acidic vaginal pH (with adequate oestrogen levels a vaginal pH is normally ranging from 3.5-5), creating therefore a hostile environment that prevents the growth of pathogenic microorganisms.

This barrier maintains proper vaginal health. When oestrogen levels drop, due to the menopause, Lactobacilli decrease in the vaginal area and the pH value increases up to 6.0-8.0, hence lower acidic levels that facilitate the growth of pathogens, such as yeasts and bacteria^[5].

This basic pH is also responsible for strong vaginal odour.

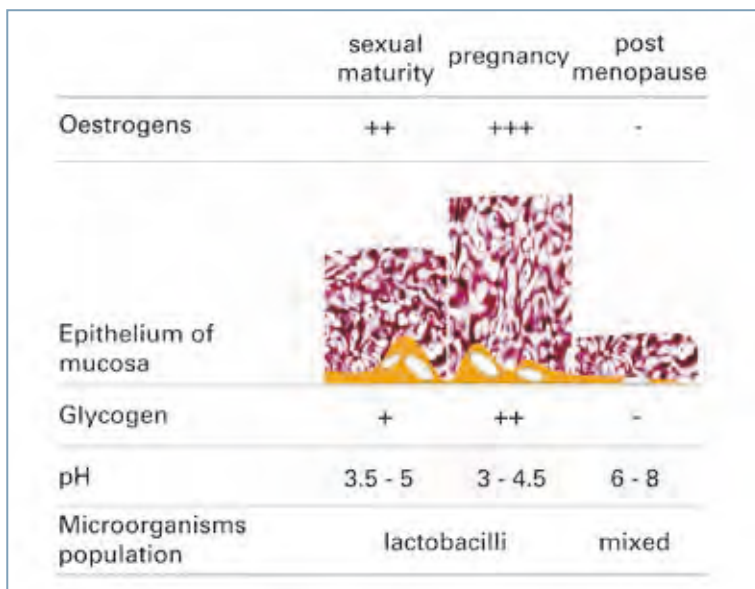


Figure 1.2 – Vaginal environment in women of different ages and physiological conditions.

1.3.4 Treatments and Therapies

We often have the impression that menopause-related symptoms, disorders and problems have just been discovered. The truth is that they have always existed, although they have not been talked about very much.

As previously stated, the most common symptoms of vaginal atrophy include dryness (estimated 75%), dyspareunia (estimated 38%) and burning sensation, discharge and pain (estimated 15%)^[5].

The principles of therapy in women with established vaginal atrophy are as follows:

- *Genital regeneration*

The reduction of oestrogen levels in post-menopausal women results in the gradual thinning of the vaginal epithelium and the rationale for the treatment of vaginal atrophy aims to restore the normal physiological conditions of these tissues.

- *Symptom relief*

Genital regeneration leads to the disappearance of many discomforting vaginal symptoms such as dryness, superficial and deep dyspareunia, vaginal bleeding, inflammation and discharge.

The following paragraphs present the most commonly used vaginal atrophy treatment options.

Middle Ages: Remedies to Eliminate Corrupted Humour

- Herbs that stimulate the menstrual flow (Emmenagogues);
- Leeches applied on the labia;
- Laxative drugs;
- Vesicant drugs.

In the 1800 remedies were developed for what was regarded as a “woman’s hell”. Tilt suggested the use of opium and cannabis, and later bromide to quieten the nervous system and “... to prevent women from drinking alcohol; poor women from drinking port and gin, and rich women from drinking wine and brandy...”

In 1886 menopause symptoms were clearly associated with reduced ovarian function, which led to the development of specific hormone therapies.

Beginning of the 20th Century

- Electroshock (Fritsch 1906), Radiotherapy (Pals 1923)
- Ovarian graft (Foà 1900), Ovary transplant (Pala 1910)
- Dry extracts of sheep ovary (Gelst & Spielman 1932)
- Placenta shakes (to drink?)
- Hypodermoclysis with the urine of pregnant women

Table. 1.1 - Different menopause treatments used in the past^[10].

1.3.4.1 Non-Hormonal Therapies, Lubrication and Rehydration Treatments

Lubricants and non-hormonal therapies for the treatment of vaginal atrophy mostly consist of a combination of soluble protective agents and non-hormonal substances that stimulate the epithelium. Lubricants are mostly used to reduce vaginal dryness during sexual intercourse and therefore do not represent a long-term solution. While oil-based lubricants should never be used with latex condoms, as they may break them, water-based lubricants can be safely used although in some women they cause burning pain due to the alcohol component and the use of preservatives. Oil and natural creams can help, but sometimes they can also cause contact dermatitis thus increasing itching and discomfort.

Hydrating substances are complex polymeric materials acting as bioadhesives that stick to the epithelial cells of the vaginal wall and to the mucins retaining water and are generally eliminated by the epithelial cell turnover. Data suggest that hydrating agents and other substances can have a long-lasting effect if used regularly. However, the controlled studies published so far show that the efficacy

of these therapies on vaginal symptoms is lower as compared with local oestrogen therapy.

Non-hormonal treatment options are especially suitable for women who want to avoid hormone therapy or for women who have a history of hormone-sensitive cancers, such as breast or endometrial cancer.

Most lubricants and hydrating agents can be purchased over the counter, but they can be also quite expensive.

1.3.4.2 Phytoestrogen-Based Preparations

Phytoestrogens are non-steroidal molecules found in plants that bind with oestrogen receptors. Soy and red clover are the primary natural sources of these molecules. Data found in the literature show that phytoestrogens have a beneficial effect on the urogenital tract. However, we should remember that these preparations are not really non-hormonal substances and have oestrogenic effects. The safety of phytoestrogens has not yet been demonstrated. Indeed, the results of epidemiological research on the intake of phytoestrogens through food cannot be considered entirely reliable. The use of phytoestrogens as nutritional supplements implies a higher intake as compared to the daily diet of the population in Eastern countries.

Also, a deep knowledge of the pharmacokinetic properties of phytoestrogens is crucial before investigating them in long clinical trials and at present the pharmacokinetics of phytoestrogens is still unknown. The level of phytoestrogens intake changes from person to person, and even in the same person, depending on their diet, the use of antibiotics or the presence of intestinal disorders.

Phytoestrogens in vivo can also lead to an anti-oestrogen response thus reducing the free floating oestrogens in the

blood stream. Finally, we have to keep in mind that the hormone-like actions of these molecules are not limited to oestrogens but also concern androgens, as they cause an anti-androgen reaction, and thyroid hormones. Anti-thyroid effects can result in thyroid gland failure, especially in situations where the iodine is low.

The risk/benefit balance of phytoestrogens in relation with breast cancer is one of the most widely discussed topics. Clinical trials conducted so far on this matter are inconclusive and further research is needed to identify the effects of phytoestrogens on the risk of breast cancer.

Since phytoestrogens are considered “nutritional supplements” their placement on the market is not subject to quality, efficacy and tolerability controls which regulate new medications.

Clinical data on the use of phytoestrogens in menopausal women do not give evidence of their efficacy and safety.

1.3.4.3 Hormone Replacement Therapy

Several studies show the efficacy of hormone replacement therapy (HRT) in the treatment of vaginal atrophy. However, the efficacy of this therapy is limited to the treatment period and does not have the so-called “memory effect” of hormone therapies. In the following paragraph we give a general overview of the spread and use of HRT from its origin up to the present time so as to better understand the recommended guidelines for the correct use of this therapy, mostly in relation to the risk/benefit balance.

But first, we have to briefly describe the types of hormones involved in HRT, which can be divided into oestrogens and progestins.

Oestrogens are the primary female hormones mostly secreted by the ovarian follicles. Oestrogens are steroid hormones that take their name from the oestrus cycle and are present in both sexes, although in women of reproductive age they reach higher serum levels as compared with men. Oestrogens are also responsible for the development of female secondary sex characteristics, such as enlargement of breasts and widening of hips, and are involved in endometrial proliferation as well as in different phenomena linked to the menstrual cycle.

Progesterone is one of the most common natural hormones and is mostly produced by the female body. Progestins are instead substances that have properties similar to natural progesterone, but are obtained by synthesis. Both progesterone and progestins are used in different fields such as the contraceptive pill and hormone replacement therapy, and are generally combined with oestrogens so as to reduce the incidence of endometrial cancer in patients with a uterus, treated with oestrogens only.

In scientific literature the term Hormone Replacement Therapy (HRT) is generally used to refer to the administration of oestrogens, either alone or together with progestins, in post-menopausal women in order to compensate for decreased oestrogen levels as a consequence of reduced ovarian function.

The use of oestrogen therapy and later of oestrogen-progestin therapy started to increase in the 1970s. In the early 1980-90s the first observational studies (mistakenly) showed the beneficial role of oestrogens, administered to menopausal women, in the prevention of cardiovascular diseases. Similarly, an improvement was detected also in the treatment of osteoporosis. Thus the role of oestrogens

changed from being purely therapeutic to preventive, not only to eliminate menopause-related disorders but also to prevent the negative outcome of other conditions that lead to illness such as cardiovascular disease or osteoporosis. With this objective in mind oestrogens were used in a larger part of the population, mostly in the US, with a massive and prolonged use of hormone therapy in menopausal women.

Women's Health Initiative

At the beginning of the 1990s, the National Institute of Health endorsed a long-term primary prevention study with a view to identifying strategies that could prevent coronary heart disease, breast cancer, colorectal cancer and fractures in apparently healthy post-menopausal women. This study is known as *Women's Health Initiative* (WHI).

The WHI consists of an observational study as well as of several clinical trials, two of which focused on the use of HRT in women with and without a uterus.

These last two trials have been carried out precisely to assess the risks and benefits of HRT, as it was expected from the evidence gathered until then, particularly as regards the decrease in osteoporotic fractures and also a 35% reduction of the risk of coronary heart disease.

The recruitment procedure for these two double-blind clinical trials lasted approximately 5 years - from 1993 to 1998 - and involved 40 US centres, so as to ultimately include 16,608 women with a uterus in the first trial and 10,739 women without a uterus in the second trial, with an age between 50 and 79, randomly assigned to receive either the treatment or a placebo.

In July 2002, the WHI trial on the use of HRT in women with a uterus was interrupted after a five-year follow up,

although originally it was supposed to last 8 years, because the risks outweighed the benefits. Women who received HR therapy showed an increased risk of developing breast cancer (26%), coronary heart disease (29%), stroke (41%) and venous thromboembolism (113% pulmonary embolism and 107% deep vein thrombosis).

The benefits included a reduction in osteoporosis-induced fractures (-34%) and in colon cancer (-37%)^[11].

The WHI is the first randomized, placebo-controlled trial that corroborates and quantifies an increased risk of breast cancer. Also, the results of the WHI clearly show that the data presented by observational studies on the prevention of coronary heart disease were incorrect.

In February 2004, the trial on women that had undergone hysterectomy was also interrupted after almost seven years of close observation because women treated with oestrogens showed a risk of experiencing strokes similar to the one detected in the trial conducted on women with a uterus who also took progestins (39% risk increase), although there was not an increase in the risk of coronary heart diseases (9% risk decrease) or breast cancer (23% risk decrease)^[11].

Overall, the results obtained from the use of oestrogen therapy only, are better than those achieved with oestrogen-progestin treatment. Therefore, the worsening effect appears to be due to the use of progestins. However, it is not possible to eliminate the use of progestins in women with a uterus because of the high incidence of endometrial cancer in therapies that only use oestrogens. It is necessary to point out that the long-term effect, also of oestrogens only, on the risk of breast cancer is still unknown.

Following the results of the WHI and of other similar studies, in December 2003 the *European Agency of the Evaluation of Medicinal Products* (EMA) stated that:

- the risk/benefit balance of HRT in the treatment of menopause symptoms that negatively affect the quality of life is positive. However, the minimum effective dose shall be administered for as short a time as possible;
- HRT cannot be considered as the medication of first choice for the prevention of osteoporosis and fractures;
- the risk/benefit balance of HRT in healthy women without menopause symptoms is generally unfavourable.

Also, the *Food and Drug Administration* (FDA) had moved in the same direction in January 2003, with the approval of new instructions for medications containing oestrogens with or without progestins. The new therapeutic indications are as follows:

- for the treatment of moderate or severe vasomotor symptoms such as hot flushes;
- for moderate or severe symptoms caused by vulvo-vaginal atrophy (such as dryness and irritation). If these symptoms are the only reason for using HRT, it would be wise to consider local treatment;
- for the prevention of post-menopausal osteoporosis. If this is the only reason for using HRT, it would be wise to consider non-oestrogen therapies and use HRT only for women whose risk of developing osteoporosis outweighs the risks of the therapy.

Regarding urogenital atrophy, it is necessary to point out that 10–25% of women who use HRT present the same symptoms, thus receiving no benefit from the systemic therapy. This data, together with the concerns around HRT safety, explain why systemic therapy is not usually recommended for women who only experience vaginal-atrophy related symptoms.

1.3.4.4 Tibolone

Tibolone is sometimes used as an alternative to HRT. Tibolone is a synthetic steroid hormone the effect of which depends on its metabolism and on the activation of peripheral tissues, acquiring properties similar to oestrogens, progestins and androgens. It has oestrogen-like effects on vasomotor symptoms and mood without stimulating the endometrium on which it has a progestogenic effect. Therefore it acts like a continuous combined hormone replacement therapy. Notwithstanding its positive action on different symptoms, Tibolone is not effective for all menopausal women. Like HRT, it is effective in the treatment of osteoporosis and while it increases the risk of breast cancer, there appears to be no increase in the risk of coronary heart diseases.

1.3.4.5 Local or Trans-Dermal Oestrogen Therapy

In the treatment of vaginal atrophy, local oestrogen therapy is to be selected when systemic therapy is not necessary for other reasons. Local therapy does indeed avoid most systemic adverse effects and is likely to be more effective in the treatment of vaginal problems.

The appropriate use of local oestrogen therapy does not require the addition of progestins for endometrial

protection. A review of the literature conducted in 2009 on the local use of oestrogens showed that no study documented endometrial proliferation after 6–24 months of use^[12]. Therefore, the literature confirms that low-dose oestrogen-based treatments are safe and do not need to be used together with progestins. However, there is no available data on treatments used for more than one year.

In the clinical practice the minimum effective dose shall be used making sure that patients do not use the selected product more frequently than is recommended. However, there may be cases where a patient needs more frequent doses in order to obtain satisfactory results. Doctors should be well aware of the fact that there is poor evidence on the safety of any vaginal product after one year of use and, consequently, patients have to be informed that in the event of unexpected vaginal bleeding they shall immediately undergo the necessary examinations.

Although the beneficial effects of local oestrogen therapy in the prevention of vaginal atrophy and of related symptoms are well known, this treatment is not recommended for women who experience vaginal/uterine bleeding of unknown cause or for women with a known/suspected endometrial cancer, as well as for women who mistrust hormone therapies.

At present, there are no guidelines concerning the duration of the therapy. The only recommendation refers to the fact that, if the therapy is used over a long period of time, a low dose should be administered. Women almost always experience a significant symptom relief after approximately 3 week treatment, although some women need 4-6 weeks before an adequate improvement can be documented^[5].

Surprisingly, little data is available in the literature on the use of local oestrogen therapies for more than six months, although it is well known that symptoms tend to reappear right after the end of the treatment. This is due to the fact that most preparations for this therapy are generally sold with a 3-6 months license for continuous use^[5]. Also, there is growing concern over the possibility that a longer use could result in endometrial disorders.

Serious adverse events are quite uncommon. However, any preparation can have moderate adverse effects and cause vaginal irritation or itching, bleeding and discharge, pelvic pain, breast pain and paresthesia. The potential effects of local oestrogen therapy as the cause of endometrial hyperplasia have already been discussed. According to all the studies conducted, there is no evidence of an increase in the risk of thromboembolism or development of metastatic disease in women with breast cancer who use vaginal tablets to mitigate the symptoms.

Generally, vaginal atrophy is the result of the treatment of many gynaecological cancers and of breast cancer that are, among other things, hormone-sensitive cancers. Squamous cell carcinoma of the cervix is not hormone-responsive, but local radiation therapy can reduce the number of oestrogen receptors and, therefore, the response to local oestrogen therapy. There is lack of data on the use of vaginal oestrogens in women with hormone-sensitive gynaecological cancers.

In the case of women with breast cancer, non-hormonal therapies have to be preferred although they can be ineffective.

1.4 CONCLUSIONS

Post-menopausal vaginal atrophy is the common cause of annoying symptoms that are the result of decreased oestrogen levels, but it is underestimated by both doctors and patients who are often reluctant to talk about it during a medical examination.

The therapy should start well before the occurrence of vaginal alterations, hence before the onset of vaginal atrophy.

Healthcare professionals should routinely open a wide and sensitive debate on urogenital health engaging post-menopausal women, in order to detect in good time symptomatic atrophy and then be able to adequately treat it.

1.5 REFERENCES

1. PRB 2011 World Population Data Sheet Population Reference Bureau.
2. *International Programs*. United States Census Bureau International Data Base. Data relative to 2011. <http://www.census.gov/population/international/data/idb/region.php>.
3. *Medical recommendations for woman in menopause. Chapter 3 - The new fifty-year-old woman*. By Age.Na.S., September 2005.
4. *Medical recommendations for woman in menopause. Chapter 5 - Symptoms*. By Age.Na.S., September 2005.
5. Sturdee DW, Panay N et al. *Recommendations for the Management of Postmenopausal Vaginal Atrophy*. International Menopause Society, October 2010.
6. Genazzani AR, Schneider HPG, Panay N, Nijland EA. *The European Menopause Survey 2005: Womens perceptions on the menopause and postmenopause hormone therapy*. Gynecol Endocrinol 2006;22:369–75.

7. Simon JA, Komi J. Vulvovaginal atrophy negatively impacts sexual function, psychosocial well-being, and partner relationships. Poster presented at North American Menopause Association Annual Meeting; October 3–6, 2007, Dallas, Texas.
8. Blümel JE, Chedraui P, Baron G, et al. Collaborative Group for Research of the Climacteric in Latin America (REDLINC). *Sexual dysfunction in middle-aged women: a multicenter Latin American study using the Female Sexual Function Index*. Menopause 2009;16:1139–48.
9. Castelo-Branco C, Palacios S, Mostajo D, et al. *Menopausal transition in Movima women, a Bolivian native-American*. Maturitas 2005;51:380–5.
10. *Medical recommendations for woman in menopause. Introduction*. By Age.Na.S., September 2005.
11. *Medical recommendations for woman in menopause. Chapter 2 - The Women's Health Initiative study*. By Age.Na.S., September 2005.
12. Al-Baghdadi O, Ewies AAA. *Topical estrogen therapy in the management of postmenopausal vaginal atrophy: an up-to-date overview*. Climacteric 2009;12:91–105.

Chapter 2

Laser: the Light in Medicine

2.1 PREFACE

The aim of this chapter is to introduce lasers and provide information to anyone who wants to know more about these devices, their applications in different fields, their principles of operation and what happens when laser beam and biological tissue interact.

Since its discovery in 1960, the laser has captured the attention of the entire scientific community. It is safe to say that over the years any technological or scientific field has been deeply influenced by this revolutionary invention. This is due to the fact that laser light has unique properties (coherence, brightness, monochromaticity and directionality) that make it different from any other source of electromagnetic radiation, either present in nature or generated by men.

2.2 HISTORICAL OVERVIEW

Although the acronym LASER (*Light Amplification by Stimulated Emission of Radiation*) is a synonym for cutting-edge and future technology, back in 1916^[1] Albert Einstein introduced the concept of stimulated emission – which is the primary laser operating principle – for reasons of energy balance.

However, only in 1960 did T.H. Maiman operate the first working laser (the Ruby Laser)^[2]. After a few months, P.P. Sorokin and M.J. Stevenson introduced Uranium and Samarium lasers^[3] (both no longer used) and, in December

the same year, A. Javan and his co-workers announced the discovery of the Helium-Neon laser, which was the first continuous-wave gas laser^[4]. What happened in the second half of 1960 caused a lot of excitement within the scientific community and many other researchers started to focus on this field. The results matched expectations: the first semiconductor lasers date back to 1962^[5], while Neodymium-doped^[6], CO₂^[7] and Argon^[8] lasers date back to 1964.

Lasers were used for the first time in medicine to treat eye disorders and in 1962 L. Goldman used the laser in dermatology^[9] (Goldman was able to recognize the minimally invasive potential of laser light in surgery). G.J. Jako used a CO₂ laser with microscope for vocal cord surgery^[10]. Over the years discoveries started to come in at lightning pace allowing for the transition from the development of few prototypes to the industrialization of devices that are now vastly popular, thanks to the wide range of applications. The work of Anderson and Parrish, who introduced back in 1983 the concept of selective photothermolysis boosting the development in the first 1990s of pulsed lasers and laser scanning systems^[11], is particularly noteworthy.

2.3 PRINCIPLES OF OPERATION

As the name itself suggests (acronym for *Light Amplification by Stimulated Emission of Radiation*), the laser is a light amplifier that uses the stimulated emission of radiations. The term “light” here acquires a wider meaning than what is generally referred to as the visible spectrum; indeed, the word “light” is the electromagnetic radiation from infrared to ultraviolet.

Lasers generally consist of laser cavity or laser optical resonator, active medium and pumping system (Figure 2.1).

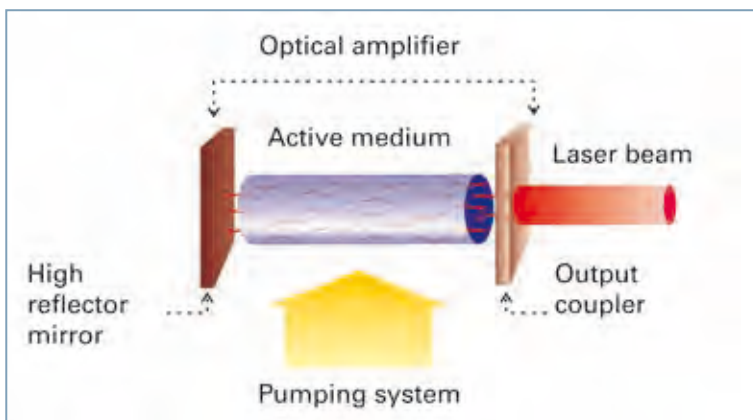


Figure 2.1 – General layout of a laser device.

The active medium is the element within which light amplification occurs. The pumping system supplies energy to the active medium which is a collection of particles – atoms, ions and molecules – in an excited state. By virtue of the basic principles of physics, each individual particle tends to go back to a ground state emitting a single quantum of light, which is a photon. Under adequate conditions it is possible to “stimulate” this emission process which allows for the amplification of the incident radiation. Within the active medium, stimulated emission can only occur at a specific wavelength that is characteristic of the absorption and de-excitation of atoms (either of molecules or ions) that form it. The laser cavity in which the active medium is located generates optical feedback. The optical resonator consists of two parallel mirrors, one highly reflective and the other partially reflective. Only the radiation that propagates in a direction perpendicular to the mirrors is amplified. Therefore, the laser light that leaks through the partially reflective mirror is highly directional. This high directionality made it possible to send a laser beam to the moon and to receive a reflection on Earth.

2.4 CHARACTERISTICS OF THE LASER BEAM

Beyond the aforementioned *directionality*, laser beams possess other characteristics that distinguish them from any other source of electromagnetic radiation: *monochromaticity*, *coherence* and *brightness*. In the following paragraphs we will examine these characteristics in details:

- *Monochromaticity*: it means that the laser beam consists of electromagnetic waves with the same frequency. While theoretically this may be true, it is not practically feasible. In fact, the laser beam consists of several wavelengths very close to one another, that is to say located in an extremely narrow band. For this reason we can talk about monochromaticity, above all as compared with the radiations emitted from any other source. In order to understand the interactive properties of lasers with biological tissues, we can regard radiation as totally monochromatic.
- *Coherence*: this feature is closely linked to stimulated emission, according to which photons have a phase relationship with each other. There are two types of coherence: spatial and temporal. Spatial coherence means that the phase difference remains the same anywhere on the wave front, while temporal coherence means that the phase difference remains the same at all times. This latter concept is closely linked to chromaticity.
- *Directionality*: as we have already seen in the previous paragraph, this property depends on the structure of the laser cavity which allows for the propagation only of laser beams that are perpendicular to the parallel

mirrors that form the optical resonator. Directionality also explains why the laser beam has a particularly limited divergence angle.

- *Brightness*: this is the primary feature of laser beams and explains their numerous applications. The brightness of a light source is defined as the power emitted per unit surface area and per unit solid angle. Lasers have a brightness level (generally one to a million) much higher than conventional light sources. This is not only due to the power emitted, but to the low beam divergence. High brightness allows for the generation of energy density able to transform to a gaseous state (to sublime) or melt the hardest metals and refractory materials.

These characteristics explain the difference between sunlight or light emitted by a normal lamp used for home lighting, and laser light. In the first case, photons are emitted in a disorderly sequence and can be compared to people leaving a cinema or the stadium, whereas in the latter case photons are organized like a squad of automatons that are all alike and march rigorously aligned.

2.5 TYPES OF LASERS

After the discovery of the first laser, this sector started to grow very quickly and there are currently so many types of lasers available that a description, albeit brief, of each one would require more space than is available in this work. The development of this sector is mostly due to the need for finding new wavelengths together with the management of emission over time (the laser waveform), and to improve performance in relation with production costs.

Laser	Active Medium	Emission	Applications	Spread
Alessandrite	Solid state	Pulsed and QS	DERMATOLOGY: hair removal, tattoos, pigmented lesions, rejuvenation.	High
CO ₂	Gas	Pulsed and continuous	Surgical ablation in different medical fields (DENTISTRY, DERMATOLOGY, GYNAECOLOGY, ENT, V ² LR, etc.), fractional laser treatments.	High
Dye-laser	Liquid	Pulsed	DERMATOLOGY: superficial vascular lesions, psoriasis.	Moderate
Diode (GaAs, GaAlAs)	Semiconductor	Continuous or pseudo-continuous	DERMATOLOGY: hair removal. DENTISTRY: surgery, tooth bleaching. PHLEBOLOGY.	High
Excimer	Gas	Pulsed	DERMATOLOGY: psoriasis, vitiligo. OPHTHALMOLOGY.	Limited
Erbium (Er:YAG or other)	Solid state	Pulsed	DERMATOLOGY: superficial surgical ablation. DENTISTRY: conservative dentistry (treatment of tooth decay).	Moderate
KTP/532	Solid state	Pulsed, QS and Continuous	DERMATOLOGY: superficial vascular lesions, tattoos, rejuvenation. DENTISTRY: tooth bleaching, periodontics, endodontics, surgery.	Moderate
Neodymium (Nd:YAG or other)	Solid state	Pulsed and QS	DERMATOLOGY: hair removal, vascular lesions. DENTISTRY: endodontics, periodontics, implantology, surgery, tooth bleaching.	High
Holmium (Ho:YAG)	Solid state	Pulsed	UROLOGY. DERMATOLOGY: vascular lesions.	Average
Ruby	Solid state	Pulsed and QS	DERMATOLOGY: hair removal, pigmented lesions.	Poor

Table 2.1 – Main characteristics of the most commonly used lasers in medicine.

There are different types of lasers depending on the active medium used: solid-state lasers (neodymium, erbium, holmium, etc.), gas lasers (CO₂ and He-Ne), liquid-state lasers (dye), and semiconductor lasers (diode), to name but a few.

The extreme variability of characteristic parameters is perhaps the feature that mostly distinguishes available

lasers. Indeed, in terms of wavelength, there are far-ultraviolet lasers with a 100 nm wavelength, up to millimetre-wavelength lasers. The power ranges from mW to MW and the waveforms are also different, allowing for different applications. A good example is the neodymium-doped laser (Nd:YAG). Indeed, there exist continuous wave-emission lasers that are used in surgery, the so-called Nd:YAG lasers which are also referred to as long-pulsed lasers (with a pulse duration of 10-100 ms) and are used for hair removal or vascular surgery. Pulsed Nd:YAG lasers with few ms are used in dentistry whereas those with higher μ s and with the so-called "*Gated-Pulse*" form are used in laser lipolysis. Finally, there is the Nd:YAG Q-switched laser (with radiation pulses of some dozens of nanoseconds) which is used for the removal of dark tattoos.

2.5.1 CO₂ Laser

The carbon dioxide laser is one of the most powerful (output power up to 80 kW) and efficient lasers (in terms of optical power to electric power ratio) ever built. It is a gas laser that uses a blend of carbon dioxide, helium and nitrogen in adequate proportions. The active medium is CO₂ while the other gases are only added to increase efficiency. This laser is pumped by an electric discharge (electrical pumping) like almost any other gas laser.

Carbon dioxide lasers can operate in either continuous or pulsed mode. Continuous-wave CO₂ lasers that deliver low power are used in medicine, while those that deliver high power are mostly used for mechanical processing.

CO₂ lasers generally emit a wavelength of 10600 nm (far-infrared laser) and have a very high affinity with water.

2.6 INTERACTION BETWEEN LASER AND BIOLOGICAL TISSUES

Interactions between laser and biological tissues have been among the first topics dealt with by researchers engaged in the development of applications of this new form of energy. Over 40 years ago, the CO₂ laser was introduced in surgical practice for the excision or removal of tissues. Later, the use of lasers in medicine grew exponentially due to several reasons:

- A growing understanding of the interaction between tissues and electromagnetic radiation, and of its effects. This allowed physicians to make a better use of the power and potential of lasers both in medicine and surgery.
- The availability of laser systems with emission wavelengths highly absorbed by molecules contained in tissues (mostly melanin, blood and water). The wavelength of laser light determines the type of interaction that takes place when the laser beam hits the biological tissue.
- The development of systems able to release energy in a controlled sequence according to a well defined waveform. This allowed for better “control” of the interaction between laser and tissue in order to obtain the desired treatment results.

Nowadays, the branches of medicine where lasers are regularly used are as follows: dermatology, gynaecology, ENT, oncology, dentistry, urology, ophthalmology, aesthetic medicine and many others. Also, the biostimulation properties of lasers are increasingly investigated and used.

It is very difficult to understand the interaction mechanism between laser radiation and biological tissues, mostly because it is impossible to assess all of the variables involved, such as the type of tissue, its composition at microscopic level, its homogeneity, as well as its thermal and conductive characteristics.

Therefore, it is necessary to proceed by approximations in order to be able to forecast the general outcome produced by laser radiation. These approximations are not only dependent on the characteristics of the tissue, but also on those of laser radiation.

A laser beam carries energy in different ways and forms that can often be selected by the user. It is necessary to point out that a higher quantity of energy available, or absorbed by the tissue, does not necessarily result in greater efficiency.

The important thing is the way in which this energy is supplied to the tissue and especially for how much time and on which area. In other words, the units of measurement that quantify electromagnetic radiations are very important in order to understand the laser-tissue interaction. In this respect we talk about:

- fluence or dose, which is the quantity of energy released per unit surface area (J/cm^2);
- power, which is the intensity of the energy released (W);
- irradiance, which is the power released per unit surface area (W/cm^2).

2.6.1 The Optical Properties of Biological Tissues

The propagation of laser light in tissue is a topic that involves many medical applications. The interaction between an electromagnetic wave and a biological tissue depends both on the wavelength and on the optical properties of the tissue itself. Notwithstanding the different structure and morphology of biological tissues, as a first approximation body tissues can be considered as homogeneous means in which the propagation of light is described through fundamental optical properties. When a laser beam is directed towards a tissue, four different interactions can take place (Figure 2.2):

- *reflection: some light reflects back off the surface;*
- *transmission: some light penetrates and is transmitted through the tissue;*
- *scatter: some photons are scattered either inwards or outwards;*
- *absorption: some light is absorbed.*

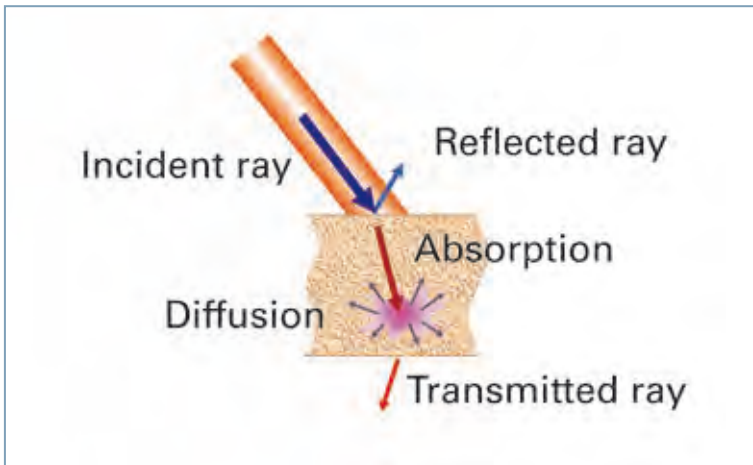


Figure 2.2 – Schematic representation of optical phenomena that occur in the interaction between laser light and biological tissue.

The relative frequency of the aforesaid events depends on the optical properties of the tissue. Reflection and scatter are caused by tissue heterogeneity. All of the effects produced on a biological tissue by laser light are based on the obvious concept that only the energy that is absorbed by the tissue can be used for medical applications. In other words, for laser light energy to have biologic effects, it has to be absorbed by the tissue (or by a component) and converted into another form of energy: thermal, chemical or mechanical energy.

As for the level of absorption of radiation caused by the lack of chemical homogeneity of biological tissues, it is highly dependent on the wavelength (Figure 2.3).

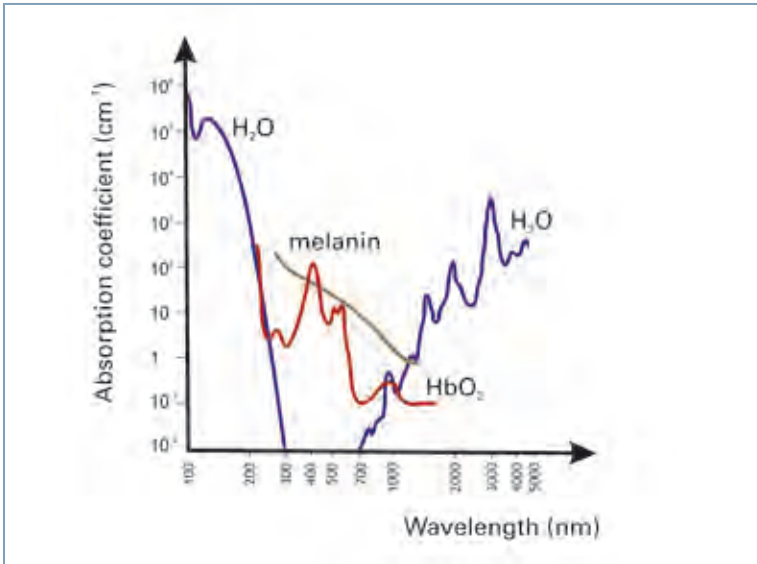


Figure 2.3 – Absorption spectrum of the main skin chromophores.

Another determining factor to characterize laser light is the waveform. As already mentioned in the previous paragraph, a laser can operate in several modes (Figure 2.4):

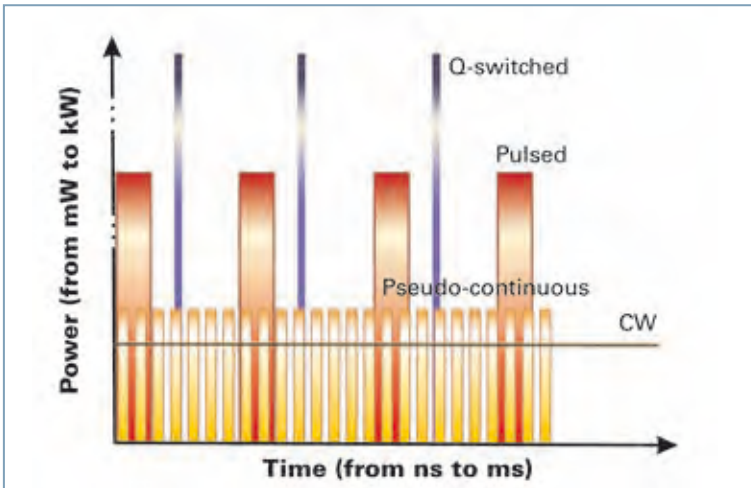


Figure 2.4 – Representation of the different laser emission forms.

- continuous (CW)
- pseudo-continuous
- pulsed
- Q-switched

Investigation and research, both from a technical and medical viewpoint, allowed for the development of different waveforms (pulsed) that are specifically directed to certain applications. By adjusting the waveform of each pulse it is possible to control the different effects caused by laser light on tissues, such as vaporization, coagulation, thermal diffusion, etc.

2.7 OVERVIEW ON THE USE OF LASER IN DERMATOLOGY

Dermatology is undoubtedly one of the medical fields in which lasers are most widely used. Skin is a natural shield

that protects the human body against the environment, including solar radiation, and therefore is particularly able to interact with light. Skin is undeniably the biological tissue that offered the best opportunity to investigate and develop treatment methods for many disorders, with the use of different laser types.

As shown, when a biological tissue is hit by a laser beam, different effects occur that depend on several factors. Some of these cannot be controlled, such as, for example, the optical characteristics of a tissue, its thermal conductivity and the presence of fluids. Other factors can instead be modified, for instance power and wavelength, pulse duration and frequency, as well as certain aspects of the laser transmission system.

Most lasers produce specific thermal effects on the tissue acting on the transformation of light energy into heat. Depending on the temperature achieved, the thermal

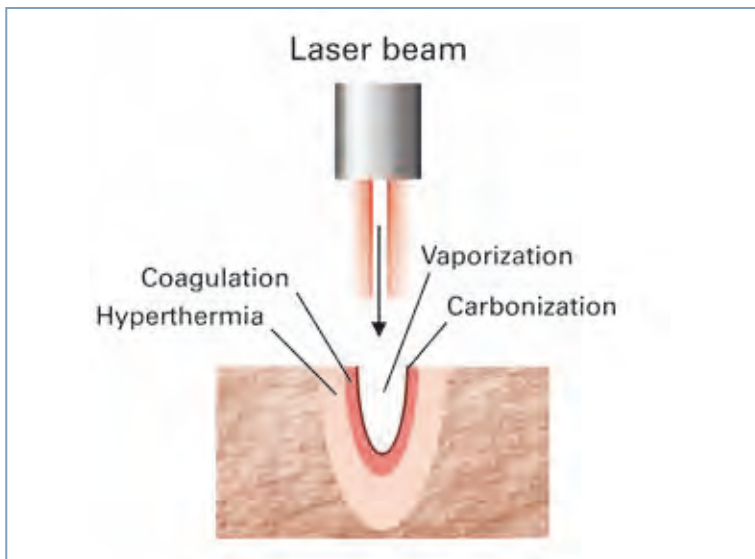


Figure 2.5 – Localization of thermal effects on the biological tissue.

energy produced is able to vaporize, carbonize, coagulate, stimulate processes or simply “warm up” (Figure 2.5).

As mentioned earlier, when talking about interaction between electromagnetic radiation and tissue not all the wavelengths are equally absorbed throughout the human body. We are aware that particular wavelengths, such as X-rays, are able to pass through the human body without being absorbed whereas others, such as the radiation emitted by Er:YAG lasers, are more easily absorbed. Absorption depends on the wavelength but also on the composition of the medium that is radiated. When we undertake such analysis, we have to remember that the human skin absorbs different wavelengths in different ways, because within the skin are components (chromophores) that absorb radiation differently. The skin chromophores that are mainly responsible for light absorption are haemoglobin (blood), melanin and water. As previously shown in figure 2.3 the absorption curves of oxyhaemoglobin, haemoglobin, water and melanin: the higher the curve the higher the absorption rate and lower skin penetration.

The following paragraphs provide information on the applications of the most common lasers, depending on the wavelength and the absorption curve of the main skin chromophores.

2.7.1 CO₂ Laser in Dermatology

The CO₂ laser was invented by Patel in 1964^[7] and today is the most commonly used laser in medicine. Its technical characteristics have already been explained in previous paragraphs. As stated, this laser emits a wavelength that is easily absorbed by the water present in most human

tissues, such as skin and mucous membranes, and produces photothermal effects. The recent development of fractional scanning systems able to perform minimally invasive rejuvenation procedures, led to an increased use of CO₂ lasers worldwide. The most advanced and cutting-edge systems allow for a careful selection of emission parameters and for a punctual control of the tissue-laser interaction based on the effect one wishes to obtain. The system is therefore able to differentiate the laser pulse depending on whether one wants to cut the skin or a mucous membrane; obtain coagulation in the presence of tissues with a higher blood supply; apply an extremely superficial thermal damage or if the treatment requires a quick superficial vaporization to later spread the heat to the underlying tissues to stimulate them.

2.7.2 Neodymium Laser (Nd:YAG) in Dermatology

The laser active medium consists of a Yttrium Aluminium Garnet (YAG) crystal doped with ionized Neodymium (Nd). The typical laser emission wavelength is 1064nm. Its radiation is moderately absorbed by melanin (especially as compared with other lasers), absorbed by blood and not particularly absorbed by water. These characteristics allow the Nd:YAG laser radiation to penetrate deeply into the skin, because of the poor absorption by water and the moderate absorption by melanin. This makes it possible to treat superficial capillaries, particularly those of the lower limbs that are located deeper beneath the skin. Another common application is hair removal, especially in dark skin. The level of absorption by the melanin is actually enough for it to be effective in the case of hair removal and, at the same time, is not as high as to damage the skin. In hair removal there is competition between the (unwanted) absorption by the

melanin in the skin and the (wanted) absorption of melanin in the hair. In order to better understand this mechanism we have to refer, as for many other laser applications in dermatology, to the theory of *selective photothermolysis* postulated by Anderson and Parrish in 1983^[11] according to which it is possible to cause a selective thermal damage by adequately choosing laser emission parameters, that is to say wavelength, pulse duration and fluence.

Since its radiation is absorbed by melanin and not by water, the Nd:YAG laser (in Q-switched mode) is especially suitable for tattoo removal (amateur, medical or post-traumatic) without leaving scars.

2.7.3 Alexandrite Laser in Dermatology

Alexandrite lasers emit at a wavelength of 755nm (between red and near-infrared) which is well absorbed by melanin. Its application is generally limited to hair removal, pigmented lesions and the treatment of tattoos. In the first case, long-pulsed lasers are used with a pulse duration of some dozens of ms. Considering the high level of absorption by melanin that is present not only in the hair but also in the skin, it is necessary to pay special attention when treating dark skin.

Q-switched lasers with pulse duration of less than 100ns are used for tattoo removal.

2.7.4 Dye Laser in Dermatology

The active medium used in a dye laser is a liquid solution that contains a particular pigment (e.g. rhodamine, coumarin, fluorescein, etc.). Each pigment has its own absorption and fluorescence spectrum that allows for the development of lasers with ultraviolet to near-infrared emissions.

In dermatology, dye lasers are used for the treatment of vascular disorders such as angioma, Port-Wine Stain and telangiectasia through selective photothermolysis. Typical wavelengths are 590, 595 and 600nm; pulse duration ranges from 450µs to 40ms in the latest generation of long-pulsed lasers.

2.7.5 Erbium Laser (Er:YAG) in Dermatology

The erbium laser emits a 2940 nm wavelength. Generally the active medium of this type of laser is an erbium-doped YAG crystal. The absorption rate of this laser by water is the highest among available lasers, producing tissue ablation from 15-20µm and a very thin layer of thermal damage (≈5µm). Due to its characteristics, the erbium laser is used for peeling in soft resurfacing since it allows for the removal of a thin layer of damaged skin or dead cells, thus reducing wrinkles and acne scars. However, due to low penetration, the erbium laser does not have haemostatic properties, unless the pulse duration is extended. Also in this case, the thermal diffusion that can be obtained with this wavelength is limited especially when compared with the CO₂ laser.

2.8 OVERVIEW ON THE USE OF LASER IN OTHER MEDICAL FIELDS

2.8.1 Ophthalmology

Laser application in ophthalmology dates back to the development of the first lasers. There are several fields of application which include, and are not limited to, retinal detachment treatment i.e. the transmission of controlled energy pulses on several points of the retina which favour

reattachment and the healing process. Glaucoma is treated by creating channels obtained through very small holes opened with the laser. The Nd:YAG laser is used to perform surgical procedures on pupillary fibrous membranes. Just one laser pulse is sufficient to section the membrane and completely open the pupil. Finally, it is also worth mentioning the widespread use of excimer laser for corneal remodelling and the correction of eye defects, such as myopia. The technique consists of the selective vaporization of the corneal tissue so as to create a new shape that, by virtue of the refraction mechanisms, corrects the existing defect.

2.8.2 Gynaecology

The CO₂ laser is used in gynaecology for the vaporization of superficial lesions on the genitals with the possibility to remove a part of the mucous membrane, as the doctor deems appropriate, and also on a wide area which is stained using special dyes so as to distinguish healthy and unhealthy tissues. CO₂ lasers are frequently used to remove genital warts by excision or laser vaporization. CN-type cervical cancers can also be treated by removing part of the tissue by excision with the CO₂ laser. This procedure is known as conization, because of the cone-shaped size of the tissue that is removed. In gynaecology the use of laparoscopy for the treatment of ovarian cancer is also widely used with CO₂ lasers or Nd:YAG fibre lasers.

2.8.3 Otolaryngology

The use of laser in ENT has become widespread, especially in hospitals. Its applications vary according to the specific sector.

In the field of laryngeal microsurgery, CO₂ laser is the gold standard especially for cancer surgery.

As for the outer ear, it can be used in otoplasty procedures instead of the scalpel. As for the inner and middle ear, laser (CO₂, diode, etc.) has proven to be successful in stapedotomy (hole in the stapes footplate due to otosclerosis) and myringotomy (hole in the eardrum due to chronic catarrhal otitis) procedures.

In mouth surgery, CO₂ laser is regarded as an effective mini-invasive method. CO₂ laser is also used in *LAUP* (Laser Assisted Uvulopalatoplasty) procedure for snoring treatment. Tonsillotomy (tonsillar reduction) is an acknowledged procedure used in paediatrics on children between 1 and 6 years of age; however, it is also successfully performed on adult patients, using CO₂, diode, or KTP laser to reduce pain.

In nose plastic surgery, excellent results have been achieved in Rhinophyma treatment. Diode, Nd:YAG and KTP laser is also used in endoscopic turbinate surgery.

2.8.4 Urology

The continuous progress in surgical lasers with fiber optics, combined with the widespread use of miniaturized endoscopic instruments able to go where a hand or scalpel could never reach, makes laser surgery the best support for the urologist and for the development of endourology. Especially holmium and thulium lasers offer advanced performance with a lower intraoperative bleeding risk and shorter hospital stays and catheterization of patients, making endoscopic procedures safer and less invasive than traditional surgical techniques and open surgery. The laser has been used since the 80's for the treatment of BPH

(Benign Prostatic Hyperplasia): after several evolutions of laser sources and surgical techniques, today the holmium laser and the more recent latest generation thulium laser, are the most advanced technology and high performance tools for endoscopic prostatectomy procedures. Even for the surgical treatment of urinary tract stones, the development of holmium lasers offers safer and minimally invasive alternatives compared to traditional lithotripsy techniques. The laser is an excellent surgical instrument widely used in surgical oncology. In urology, several kinds of laser (mainly Ho:YAG, Tm:YAG and Nd:YAG) can be used for the excision of tumors of the urethra, bladder, ureter and kidneys.

2.8.5 Dentistry

In dentistry different types of lasers are used for a wide range of applications, from the treatment of tooth decay, to periodontal pocket decontamination, tooth bleaching, surgery of the oral mucosa, etc. The most widely used lasers in this field are:

- CO₂ laser with a 10600 nm wavelength, which is mostly used in oral surgery (frenectomy, excision of gum tissue, removal of small cancers affecting the mucosa and of infected salivary glands, vaporization of other conditions such as leukoplakia, etc.).
- Er:YAG laser with a 2940 nm wavelength, which is mostly used in conservative dentistry (treatment of tooth decay) and oral surgery.
- Nd:YAG laser with a 1064 nm wavelength. Thanks to its excellent properties it is used for decontamination procedures in Endodontics (root canal therapy) and Periodontics (treatment of periodontal pockets).

- KTP laser with a 532 nm wavelength, which is widely used for many applications, from tooth bleaching (effective also in the case of intrinsic staining, such as tetracycline stains) to oral surgery, endodontics and periodontics.
- Diode laser with a wavelength of 810-980 nm, which is widely used also because of the availability of cheap systems, although they do not always possess adequate characteristics. It is mostly used for oral surgery and tooth bleaching (although only to treat extrinsic staining, such as tobacco/coffee stains, etc.), as well as in endodontics and periodontics.

2.8.6 Oncology

The use of laser equipment allows for the removal of cancers with a reduced development of cancer cells. Furthermore, in the case of cancers that receive large blood supplies, the use of a slightly defocused CO₂ laser, allows for the vaporization of the cancer and, simultaneously, the haemostasis of blood vessels with a diameter of up to 500µm.

In regard to small cancers, metastasis and lymph nodes, a technique has been developed to generate the hyperthermia (overheating) of cancer cells, hence denaturing the biological tissue. Thanks to the support of an echograph, a special needle is inserted until it reaches the tumour which needs to be destroyed. An optical fibre is then introduced to transport the radiation emitted by the Nd:YAG laser. The laser light is absorbed by biological tissues the temperature of which increases until they are irreversibly damaged.

In the field of ENT, different methods have been developed for the ablation of vocal cords through the use of a CO₂ laser with short pulses with a high peak power, in order to limit damage to healthy tissue surrounding the area to be destroyed.

2.8.7 Treatment of Arrhythmia

Through ablation with laser light, delivered to the chest cavity by fibre optic introduced via suitable catheters, it is possible to interrupt some electrical conduction pathways inside the heart, hence reducing the risk of experiencing arrhythmia.

2.8.8 Biostimulation

Through mechanisms which are not yet fully understood, photostimulation with laser light shows therapeutic effects on disorders such as rheumatism or rheumatoid arthritis, trauma injury, oedema, insufficient peripheral blood flow, bedsores and ulcers. Medical statistics provided evidence of many positive case studies in this respect.

The objective data documented so far show an increase in lymphatic drainage following biostimulation and a gradual relief of the pain experienced by the patient. The therapy known as HILT® (*High Intensity Laser Therapy*) is particularly noteworthy. It consists of the use of a special Nd:YAG laser that emits high power peak pulses able to treat painful disorders affecting the musculoskeletal system, either superficial or deep disorders.

2.9 OVERVIEW ON THE USE OF LASER FOR ART CONSERVATION

With regard to art conservation, lasers with a suitable power density can be used to clean bronze or stone art pieces. In this field, a focused laser beam is used to vaporize a thin layer of material impregnated with foreign substances or whose chemical composition has been changed due to the action of external agents.



Figure 2.6 – Cleaning and restoration of the Rape of the Sabine Women by Giambologna (Loggia dei Lanzi – Florence) carried out in 2001 using laser technology.

2.10 REFERENCES

1. Einstein A. *Zur Quantentheorie der Strahlung*. Physikalische Gesellschaft Zürich 1916;18:47– 62. The same paper was published on 15 March 1917, *Physikalische Zeitschrift* 1917;18:121–128.
2. Maiman TH. *Stimulated optical radiation in ruby*. *Nature* 187, 493 - 494 (06 August 1960); doi:10.1038/187493a0.
3. Sorokin PP, Stevenson MJ. *Stimulated infrared emission from trivalent uranium*. *Phys. Rev. Lett.*, vol. 5, pp. 557–559, December 1960.
4. Javan A., Bennet WR Jr, Herriot DR. *Population inversion and continuous optical maser oscillation in a gas discharge containing a helium neon mixture*. *Phys. Rev. Lett.* , Vol. 6, p 106-110, February 1961.
5. Hall RN, Fenner GE, Kingsley JD, Soltys TJ, Carlson RO. *Coherent Light Emission From GaAs Junctions*. *Physical Review Letters* 9 (9): 366–369. November 1962.

6. Geusic JE, Marcos H M, Van Uitert LG. *Laser oscillations in nd-doped yttrium aluminum, yttrium gallium and gadolinium garnets*. Applied Physics Letters 4 (10): 182. 1964.
7. Patel CKN. *Continuous-Wave Laser Action on Vibrational-Rotational Transitions of CO₂*. Physical Review 136 (5A): A1187–A1193. 1964.
8. Bridges WB. *Laser oscillation in singly ionized argon in the visible spectrum*. Appl. Phys. Lett. 4, 128 (1964); erratum: Appl. Phys. Lett. 5, 39 (1964).
9. Goldman L, Blaney DJ, Kindel DJ, Franke EK. *Effect of the laser beam on the skin*. J Invest Dermatol 1963;40:121–122.
10. Strong MS, Jako GJ. *Laser surgery in the larynx. Early clinical experience with continuous CO₂ laser*. Ann Otol 1972;81:791.
11. Anderson RR, Parrish JA. *Selective photothermolysis: precise microsurgery by selective absorption of pulsed radiation*. Science 1983;220:524– 527.
12. Masotti L. *Alcune riflessioni sul laser e i suoi impieghi*. 1995.
13. Galli M. *Interazione laser-tessuto*. In: Campolmi P, Bonan P, Cannarozzo G. *Laser e sorgenti luminose in dermatologia – Cap 1*. Ed Masson. Maggio 2003.

Chapter 3

***MonaLisa Touch*[®]: the First Laser-Assisted Technology for the Treatment of Vaginal Atrophy**

In the field of observation, chance favours only the prepared minds.

Louis Pasteur

3.1 INTRODUCTION

The previous chapters provided introductory information on vaginal atrophy and laser technology and now we can present the new *MonaLisa Touch*[®] technology.

To better understand how innovative and unique this treatment is, it is important to know the background that allowed for its design and development. First of all, it is necessary to say a few words on the company that conceived this technology. DEKA has been in existence for more than thirty years ago and is now one of the main medical companies of a large industrial group operating in the field of optoelectronics. Thanks to its own technology and multidisciplinary knowhow, DEKA is able to manufacture laser sources and systems for a wide range of applications.

Thanks to its wide experience and valuable knowledge, DEKA is a leading company in the field of laser-assisted medicine. Its history is indeed a thirty-year long path through research and trials that allowed it to develop cutting-edge systems and innovative methods, with a view to turning any discovery into real benefits.

Scientific research has always been a fundamental strategic choice for DEKA and with the aid of large investment, it has tried to develop new ideas for new applications in the medical field. Since its inception, DEKA has been promoting and cooperating in research projects with many research centres both in Italy and abroad. The company is also constantly engaged in clinical trials and histology analyses, counting upon the support of its own laboratories and of qualified national and international centres. DEKA is therefore able to assess the efficacy and safety of any new laser treatment, for each of the different sectors in which it operates (dermatology, gastroenterology, ENT, gynaecology, ophthalmology, dentistry, oncology, etc.), before introducing it to the market.

The new *MonaLisa Touch*® technology was developed thanks to synergy of multidisciplinary approaches.

3.2 DEKA AND THE CO₂ LASER

The experience of DEKA in the production of the first CO₂ laser for dermatology, surgery and therapy dates back to the 1980s. In those years, the CO₂ laser was considered as a surgical tool able to cut, vaporize and coagulate biological tissues. In fact, the CO₂ laser was already used to practice what is known as *Low Level Laser Therapy*, due to its stimulating action on conditions such as rheumatism, rheumatoid arthritis, post-trauma injuries, oedema, insufficient peripheral blood flow, bedsores, venous ulcers, etc.

As for the application of the CO₂ laser in surgery, and mostly in Gynaecology and ENT, in the years that followed, more and more advanced systems have been developed with high precision scanning systems and micromanipulators able

to release special high peak power pulses (up to 1000 W) and very short emission times (dozens of microseconds). However, dermatology and aesthetic medicine are the sectors that brought CO₂ lasers to the limelight in recent years thanks to the new *DOT Therapy* which is a fractional treatment for skin rejuvenation.

3.2.1 DOT Therapy: the Innovative Micro-Ablative Skin Rejuvenation Treatment

Ablative skin resurfacing with a CO₂ source has always been regarded as the gold standard in laser surgery for the treatment of wrinkles and damage due to skin ageing. The first publications on this method date back to the end of the 1980s. The treatment consists of the use of a scanning system that quickly moves a laser

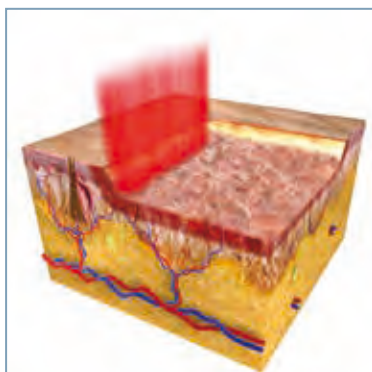


Figure 3.1 – Removal of the outermost layers of the skin (ablation) with uniform, non-fractional scanning (traditional *Skin Resurfacing*).

beam over an area of a few square centimetres removing the outer layers of the skin. It can be performed either on limited areas (such as, for example the area around the eyes and the mouth) or on the entire face (full face treatment). However, due to prolonged healing times, the delicate skin care and dressing after the procedure, as well as possible side effects that cannot be neglected, the spread and popularity of this technique has always been very limited. Indeed, over the years the interest of the market mostly focused on minimally invasive systems and methods, both because of the needs of patients who cannot stop working or reduce their social activities for a long period of

time, and of the incidence of possible side effects, as well as the need to simplify aftercare. This situation led to the development of new methods and protocols that combine efficacy with reduced healing times.

To this end, in the years 2003-2004 a new minimally invasive treatment that used a fractional laser system to perform non-ablative skin rejuvenation was developed. Its technology was highly innovative in the sense that it introduced the idea of radiating the skin with a fractional system, rather than a selective one. The non-ablative laser only damages certain zones in the selected target area, while not harming any surrounding healthy untreated tissue. This last feature is precisely what distinguishes fractional treatment from traditional treatment. As soon as the unhealthy tissue is treated, the healing process starts helped and accelerated by the healthy untreated tissue surrounding the treated tissue that spreads in the damaged area with new cells. It is quite easy to understand the advantages of this method. First of all, it is minimally invasive with short healing time. However, it has also a disadvantage that cannot be neglected, which is a lower efficacy hence the

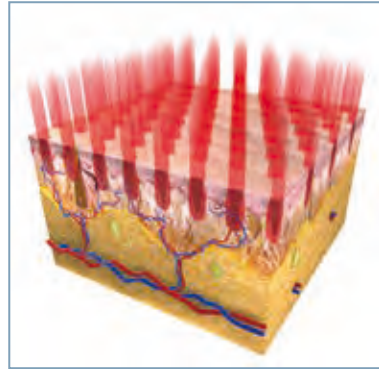


Figure 3.2 – Thermal denaturation of the skin produced by a non-ablative fractional laser (Non-ablative fractional skin rejuvenation).

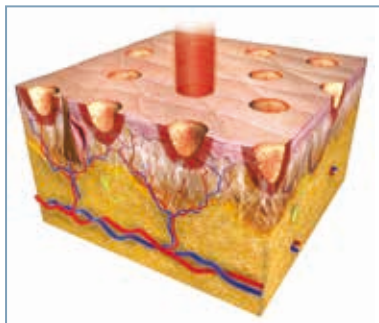


Figure 3.3 – Removal of the outermost layers of the skin (ablation) with fractional scanning (DOT Therapy or Fractional Skin Resurfacing).

need to replicate the treatment, over several sessions, in order to satisfy the patients, especially those with clear and evident ageing marks.

Thanks to the experience gathered in the development of CO₂ lasers with scanning system, in 2004 DEKA started the development and clinical validation of what would become known all over the world as *DOT Therapy* or *Fractional Skin Resurfacing*, that is to say micro-ablative skin rejuvenation. The start-up idea was quite simple: combine the advantages of traditional *Skin Resurfacing* performed with the CO₂ laser, with those of the new non-ablative fractional technique, while eliminating the disadvantages of both technologies. If fractional treatment allowed for shorter healing times because of the aforesaid reasons, than why not use this same procedure also for the CO₂ laser which undoubtedly offered greater efficacy?

The results obtained were really astonishing and led, after accurate clinical and histology validations, the introduction to the market of *SmartXide DOT* and the now globally recognised *DOT Therapy* (to see how popular this therapy is, enter on any search engine the words "*DOT Therapy Laser*" and "*SmartXide DOT*").

It is worth stressing that the numerous CO₂ systems currently present in the market, thanks also to the success of this technology, are only apparently based on the same principle of operation. In fact, they have different technical characteristics (output power, pulse form and duration, scanning system, *Stack* function with fractional emission also over time, distance between scanning points) that have obvious repercussions on clinical outcomes and recovery times. Without going too much into detail, it might be useful to better understand the principle of operation of *DOT Therapy* which is closely linked to the

characteristics of DEKA systems. Natural ageing effects, exposure to sun light and air pollution result in the gradual skin's deterioration, its structure and functions. In order to "rejuvenate" the skin, eliminating the outermost layers thus reducing the wrinkles, is not enough. It is important to treat in-depth so as to stimulate the skin to produce new collagen and new structure of the extracellular matrix that, like scaffolding, will support the outermost layers. Although this concept might be easy to understand, it is difficult in practice. By stimulating the skin in-depth there is a risk of damaging the outer layer of the skin whose physiological function is to protect the human body. In order to stimulate the dermis and, at the same time, preserve the surface of the skin, DEKA developed two exclusive technologies that distinguish *DOT Therapy* from any other similar treatment: *SmartPulse* and *SmartStack*.

3.2.1.1 SmartPulse: Pulsed Emission Technology

By combining clinical knowledge and technology, DEKA developed a special pulse for its CO₂ lasers used for fractional *Skin Resurfacing* treatment, so as to obtain ablation and heat denaturation with one single pulse. The high peak power that characterizes the first part of the *SmartPulse* allows for the release of a large quantity of energy in a very short time for quick ablation of the epidermis

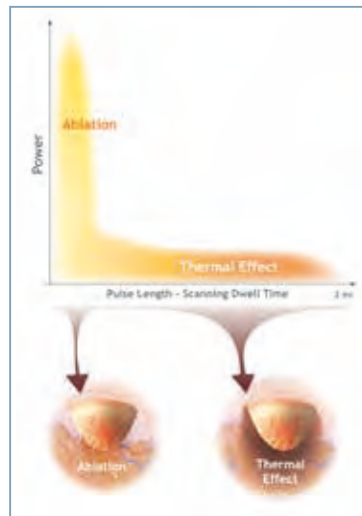


Figure 3.4 – *SmartPulse*: ablation and thermal denaturation, two effects with one single pulse.

and of the first layers of the dermis which are less rich in water. After this quick vaporization, the pulse energy spreads heat through the dermis, a tissue rich in water.

Thus the dermis receives the appropriate stimulation for immediate shrinkage and new collagen production. At the same time the damage caused to the epidermis is very little and healing time very short.

3.2.1.2 SmartStack Function

This technology allows for a careful control of the vaporization depth of the skin and of the thermal action, emitting successive pulses in the same area, for a *Stack* variable ranging from 1 to 5. Using a *Stack* level above 1 allows for a fractional impulse over time.

This function allows the skin to cool down between two successive pulses and minimizes thermal damage. The risk of unwanted side effects is further reduced, especially on particularly sensitive areas and in people with dark skin or Asian phototype. Also, with a greater ablation depth, for example in the treatment of scars, the *SmartStack* allows for this depth while avoiding heavy bleeding and lengthy healing times.

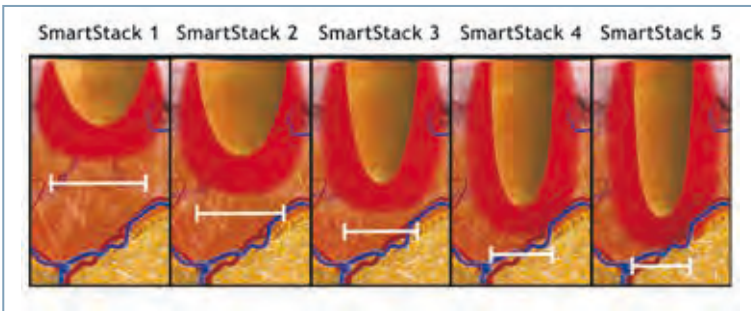


Figure 3.5 – Effect of laser pulses on the skin depending on the increase in the *SmartStack* level. There is a gradual narrowing of the ablation channel due to a greater shrinkage effect.

3.3 FROM SKIN REJUVENATION TO VAGINAL REJUVENATION

Curiosity, which is essential to researchers if they are to make new scientific discoveries, led DEKA to explore the possibility of applications of *DOT Therapy* in sectors other than Dermatology and Aesthetic Surgery. Although putting “face skin” and “vaginal mucosa” side by side might seem unusual, but we have to take into account the long experience of DEKA in the production of CO₂ laser systems for Gynaecology. In 2008, this experience allowed DEKA to undertake the first trials that would later lead to the development of *V²LR (Vulvo-Vaginal Laser Reshaping)* and, more specifically, the *MonaLisa Touch®* treatment.

The starting point was the evident “rejuvenation” effects on tissues, following fractional treatment with a CO₂ laser. At this point, it is important to focus on the concept of rejuvenation. In a more general sense, the term “rejuvenation” is always associated with aesthetics and, therefore, with something almost superficial. Eliminating wrinkles for example can have psychological effects on the self-esteem of the patient, but has no “therapeutic” effect. This is not entirely true. When we age, all the parts of our body (cells, tissues, organs, apparatuses and anatomical structures) lose their functions. In some cases this has no major implications, but sometimes it leads to more serious problems. Let’s think for example about brain cells, musculoskeletal apparatus or the eye. If it were possible to “rejuvenate” them it is easy to imagine what important therapeutic effects could be achieved. The same concept holds true for vaginal mucosa. As widely discussed in the first chapter of this book, ageing in women, linked to menopause, involves various organs, including the vagina, and generally resulting in vaginal atrophy. If a treatment

was able to “rejuvenate” the vaginal mucosa, restoring its pre-menopausal structure, then it is reasonable to think that vaginal atrophy related problems too would benefit from it. As we will see in the following paragraphs, this is precisely what we can obtain with the *MonaLisa Touch*® which can correctly be referred to as a vaginal rejuvenation laser treatment, although we have to be careful not to confuse it with *Laser Vaginal Rejuvenation* therapies that are now very popular especially in the US.

3.3.1 Skin Versus Vaginal Mucosa

Before giving a thorough description of the procedures and results of the research carried out, it is necessary to focus on the similarities and differences between skin and vaginal mucosa.

Skin: the cutis or skin is a robust laminar structure that covers our body.

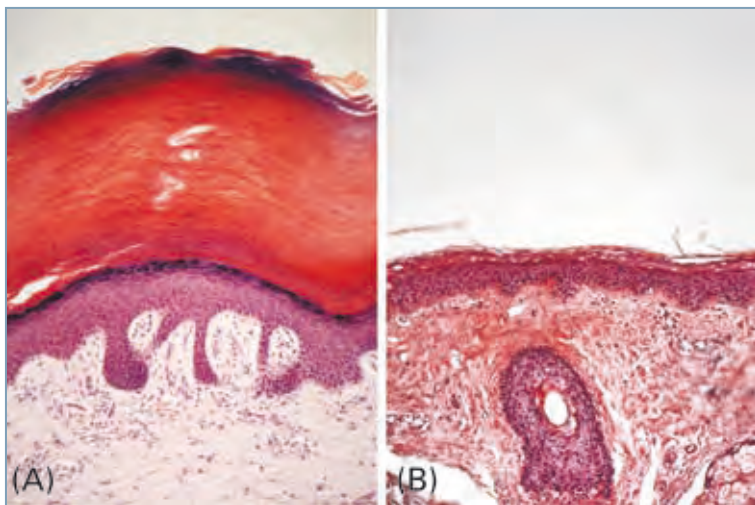


Figure 3.6 - Histological preparations of thick (A) and thin (B) skin stained with haematoxylin and eosin (H&E). [Courtesy of Prof. A. Calligaro – University of Pavia].

The skin consists of three layers:

- Epidermis: it is a stratified squamous epithelium that regenerates continuously thanks to a dynamic process in which the proliferating cells of the stratum basale replace the spinosum, granulosum and corneum strata. The stratum corneum (cornified layer) is composed of thin sheets of keratins that continuously shed from the surface of the skin.
- Dermis: it consists of dense connective tissue, with collagen and elastic fibres as support, and ground matrix, rich of blood and lymphatic vessels, nerve fibres and endings, and glands. The ground matrix is rich in polysaccharides and glycoproteins that make it highly permeable thus favouring the trophism of the whole skin, included the epidermis which, as any epithelium, does not contain vessels.
- Hypodermis: it lies below the dermis and its purpose is to anchor the skin to the deep common fascia. When the hypodermis is particularly rich in adipose tissue, it is referred to as subcutaneous panniculus adiposus.

Vaginal mucosa:

The vagina is a canal and is the latest tract of the female genital apparatus.

It has the same structure of the hollow organs and consists of a tunica mucosa, tunica muscularis and tunica adventitia. There is no submucosa.

The tunica mucosa (that is to say the vaginal mucosa) consists of vaginal epithelium and lamina propria (Figure 3.7):

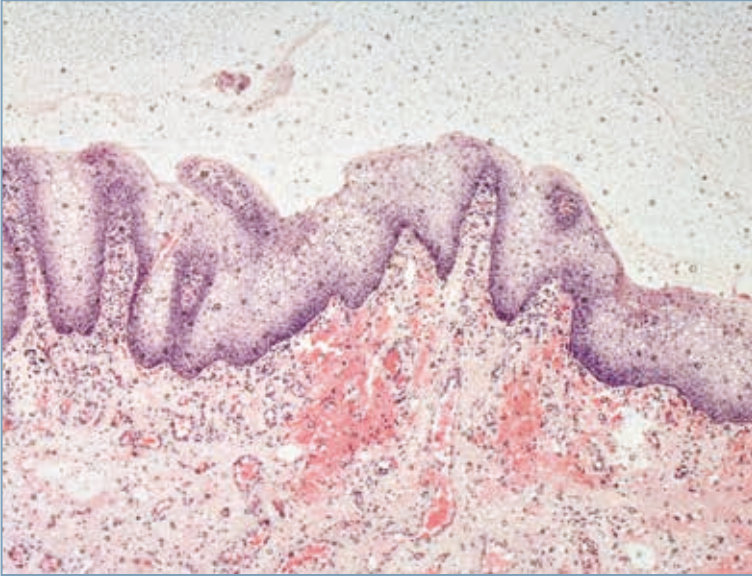


Figure 3.7 – Histological preparation of vaginal mucosa stained with haematoxylin and eosin (H&E).
[Courtesy of Prof. A. Calligaro – University of Pavia].

- The vaginal epithelium is a multilayered, nonkeratinized squamous epithelium. It regenerates thanks to a dynamic process that starts with the proliferation of the cells of the stratum basale and ends with the shedding of the most superficial cells.
- The lamina propria lies below the epithelium and is arranged in papillae. It consists of connective tissue, rich in collagen and elastic fibres. It contains vessels, mostly capillaries, and lymphocytes while there are no glands. It is responsible for the support and trophism (nutrition) of the vaginal lining and is fundamental for the architecture of the vaginal wall.

To better understand the studies that will be presented in the following paragraphs, it is important to focus more on the ground of the connective tissue, generally referred to as ground substance. It consists mainly of

macromolecules known as proteoglycans, which are attached to long chains of hyaluronic acid through special proteins. Proteoglycans have the ability to retain large quantities of water. The high hydration level of the lamina propria depends on proteoglycans. The richness in water of the extracellular matrix means turgidity of the mucosa that cooperates with the supporting function of well structured collagen. The high presence of water molecules results in a higher permeability which favours the metabolism of the mucosa in terms of an easier transport of metabolites, nutrients, etc. from capillaries to tissues (i.e. lining epithelium, connective tissue, fibres and nerve endings) and the drainage of waste substances from tissues to blood and lymph vessels. If the ground substance is poor or does not contain much water, the epithelium will not receive the nutrition necessary for its correct development or proper hydration.

Finally, it is worth saying something more about fibroblasts, considering the critical role they play. Fibroblasts are the most widespread cells in the connective tissue. They are able to produce and elaborate fibres (i.e. collagen, reticular and elastic fibres) as well as the components of the ground substance of the connective tissue (i.e. hyaluronic acid, proteoglycans and glycoproteins), controlling their organization as well as other activities. After secreting the components of the extracellular matrix, fibroblasts remain trapped among the fibres and are called fibrocytes, which are quiescent, surrounded by collagen fibres. Tissue damage stimulates fibrocytes to become active fibroblasts and synthesize new collagen.

A significant difference between vaginal mucosa and skin lies in the structure of the epithelium. The outermost layer

of the skin, continuously subject to mechanical stress, is the stratum corneum which is made up of several layers of dead flat cells entirely filled with keratin. Its thickness varies depending on the body region and in the areas more subject to mechanical stress the layer is generally thicker. It is rich in keratin and extremely poor in water.

On the contrary, the epithelium of the mucosa is nonkeratinized and is rich in water and glycogen.

These differences have large implications, both for medicine and technology, as is the focused objective of this publication. As already stated, the CO₂ laser has a high affinity with water. Due to their different levels of hydration, the effect of laser absorption by the skin or the mucosa will not be the same.

More specifically, in order to stimulate the skin dermis in depth and the lamina propria (of the mucosa), we have to overcome two different kinds of barriers. As previously mentioned, DEKA developed a special pulse, known as *SmartPulse* to be used for *DOT Therapy*.

This favours the quick vaporization of the epidermis, without causing damage, and allows for the spread of the laser beam deep through the skin. Considering what we have just said, the barrier to be overcome in the vaginal mucosa has very different characteristics.

A laser that has been conceived for skin rejuvenation does not have the same efficacy in the rejuvenation of the mucosa. That is why DEKA, thanks to its experience in the field of dermatology, developed the *SmartXide² V²LR* system (Figure 3.8), dedicated to the *MonaLisa Touch[®]* treatment, able to release energy through a special pulse while taking into account the peculiar features of the vaginal mucosa: the *DEKA-Pulse* or *D-Pulse* (Figure 3.9).

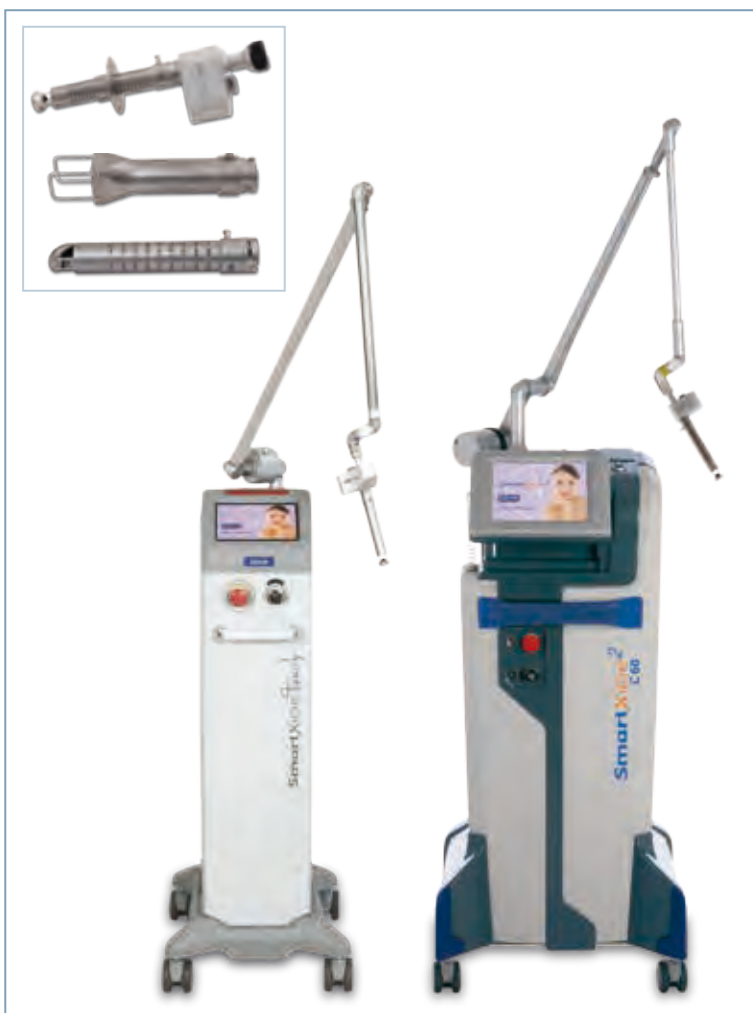

Figure 3.8 – CO₂ laser systems SmartXide² V²LR and the new SmartXideTouch V²LR, produced by DEKA with fractional scanner HiScan V²LR for the *MonaLisa Touch*[®] treatment (patent application already filed).

As shown in the figure 3.9, the DEKA-Pulse consists of:

- an initial part with constant, high energy peak power, for rapid superficial ablation of the epithelial component of atrophic mucosa characterized by low water content;

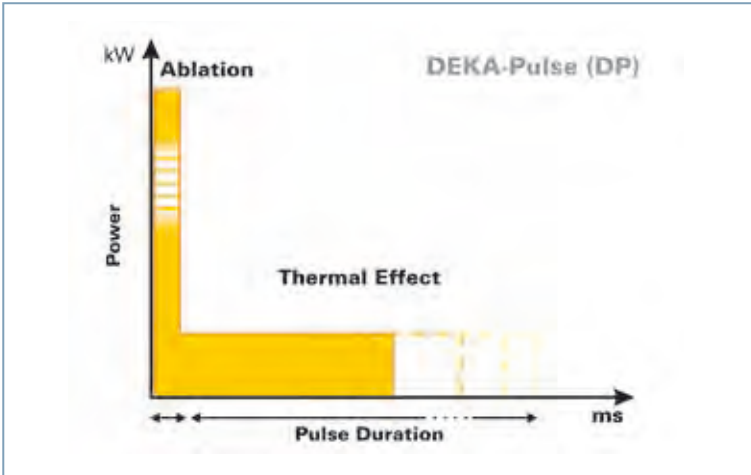


Figure 3.9 - DEKA-Pulse: the pulse specifically developed by DEKA for *MonaLisa Touch*[®] treatment.

- a second variable part, with lower peak power and longer emission times, that allows the laser energy heat to penetrate in depth, stimulating the synthesis of new collagen and of the components of the ground substance of the matrix.

3.4 FROM CLINICAL INVESTIGATION TO THE NEED FOR AN ULTRASTRUCTURAL IN-DEPTH ANALYSIS

The results obtained from the first trials carried out in 2008 have been highly encouraging. As you may well understand, we needed time and passion to develop the various aspects related to a completely new method (dedicated scanning system, appropriate pulse, treatment protocol, medical procedure, etc.). The numerous case studies collected over the years enabled us to gather very important data, the analysis and assessment of which made it possible to develop this new technique. In 2011,

an article was published in *"The American Journal of Cosmetic Surgery"* relative to the experience of a team of gynaecologists from the University of Mendoza, Argentina, who treated 92 menopausal women from December 2009 to December 2010 following an experimental protocol^[1]. The assessment questionnaires, filled in by the patients, show significant improvements following the treatment as regards problems related to vaginal dryness (in 67.5% of cases), dyspareunia (62.5%), and irritation or burning pain (50%). Although the questionnaires can be standardized and the assessment made as objectively as possible, there still lacked the possibility to unequivocally demonstrate the "rejuvenation" of the mucosa. While in cases of wrinkle or stain removal treatments simple "before and after" pictures are enough to convince anybody of the efficacy of the applied method, this does not hold true in the case of the treatment of vaginal atrophy. This awareness led to the development of a method the purpose of which was to give evidence of the "functional" improvement of the vagina. In the study published by the Argentine medical team, a first survey had also been conducted with histology images showing an increase of the epithelium and of the quantity of collagen in the connective tissue. It is necessary to remember that while numerous papers on the anatomy and physiology of the skin have been published, the knowledge base is limited when it comes to vaginal mucosa. Therefore, the knowledge base necessary to carry out a correct and accurate histological examination was still lacking. Thanks to the cooperation of the IRCCS *San Raffaele* Hospital of Milan and the University of Pavia it was possible to conduct a survey focusing on the effect of CO₂ laser treatment on the vaginal mucosa and identifying the best treatment protocol.

3.5 MICROSCOPICAL AND ULTRASTRUCTURAL OBSERVATIONS ON THE VAGINAL MUCOSA AFTER A CO₂ FRACTIONAL LASER TREATMENT

In this first study, post-menopausal women with an anterior vaginal wall prolapse underwent treatment with the CO₂ fractional laser *SmartXide² V²LR*. The purpose of the study was to assess the modifications of tissue morphology based on different treatment conditions (output power, exposure time, distance between single points, Stack level and total energy fluence).

After in vivo treatment and surgical excision, mucosa samples have been treated with specific protocols for laser radiation and for observations under optical microscope and electron transmission microscope.

We mostly focused on modifications of both the extracellular matrix of the mucosa and on cellular components more directly involved in its trophism, although there was a lapse of time between treatment and sample fixation.

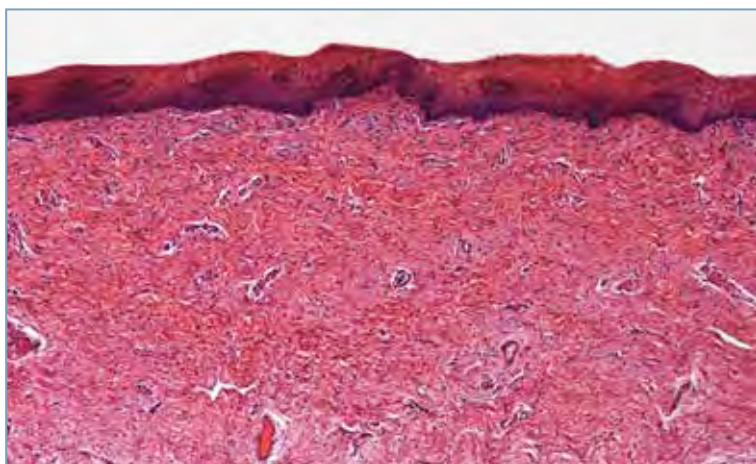


Figure 3.10 - Histological preparation of a vaginal mucosa section stained with haematoxylin and eosin (H&E). This image shows basal conditions of a post-menopausal patient undergone treatment with SmartXide² V²LR system. This morphological picture indicates vaginal atrophy at a marked stage, with a thin epithelium (with small size cells), no superficial desquamation and thick under-epithelium connective tissue (with "old" dense collagen). It is also possible to observe residual atrophic papillae.

The observations conducted on the extracellular matrix of the mucosa showed significant modifications in the morphology of collagen fibres, most likely due to varying temperature increases in the area involved.

Following treatment with the CO₂ fractional laser, observations under the optical microscope showed different areas of the mucosa, with varying extension depending on the higher or lower fluence used in the different protocols tested (Figure 3.11):

1. Vaporization crater and 2. Carbonization area the interaction with the pulsed emission of the laser beam and the vaginal mucosa causes a sudden rise in temperature in the tissue involved, which “vaporizes” the most superficial structures (all the epithelium and up to 1mm of the connective tissue for higher energy protocols) that have a high water content and a thin layer of “carbonization” of the remaining superficial structures.

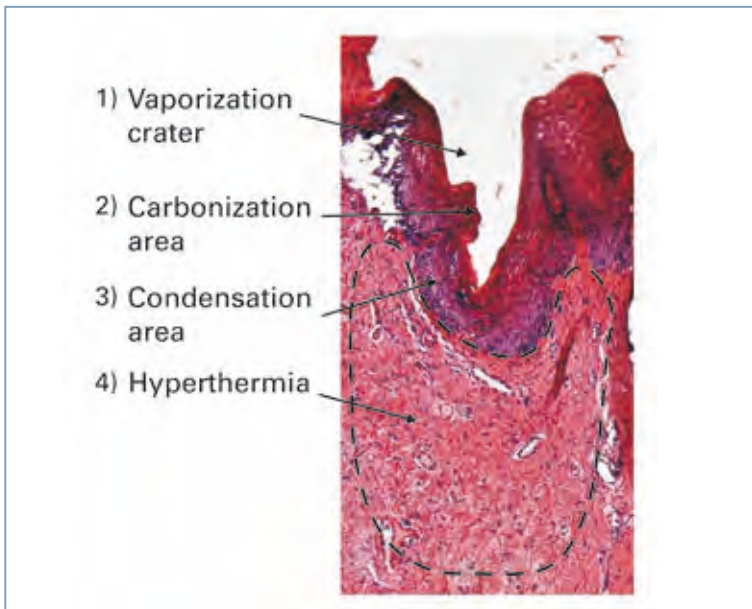


Figure 3.11 – Histological preparation of vaginal mucosa stained with haematoxylin and eosin (H&E). There are four different areas following the CO₂ fractional laser treatment *SmartXide² V²LR*.

3. Condensation band: the connective tissue below the carbonization crater also loses water. A strip of material more intensely red stained is highlighted, where there is a concentration of collagen by virtue of thermal coagulation. The temperature gradient produces different effects on the tissue, mainly consisting of collagen, which is a “contraction” of the fibres above 65°C and a denaturation between 50 and 65°C. The width of this area varies with energy in a nonlinear way depending on the protocol used (the width ranges from 50 to 110 µm). Denatured collagen creates a form of thermal barrier to the underlying mucosa.
4. Traditional microscopy does not show particular effects on the area below the condensation band. There are scallop-shaped bundles of collagen fibres, vessels and other structures normally present in the connective tissue, while it does not detect the presence of other cell types that can be related to an inflammation, such as lymphocytes, plasma cells, mast cells or other cells typical of inflammation. There is an increase in temperature on the outermost part of this area. It is important to remember that at 45°C the Heat Shock Protein (HSP) response takes place, which can only be switched on by undamaged and fully functioning cells. HSP47 in particular is able to stimulate fibroblasts to synthesize new collagen.

3.5.1 Polarized Light Microscopy

Subsequently, we analysed polarized light microscopy images. The polarized light microscope is designed for the observation of tissues that are visible especially because of their “optical anisotropy”. In other words, highly organized structures are highlighted while disorganized structures (optically anisotropic structures) appear dark.

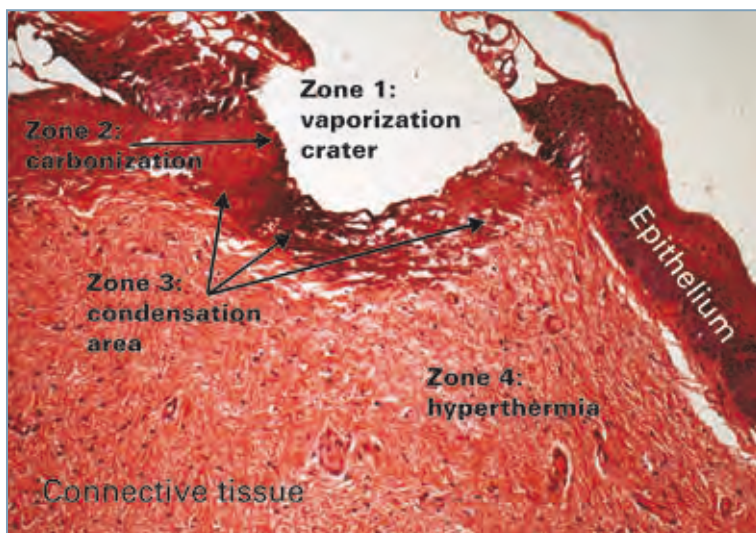


Figure 3.12 – Histological preparation of a section of the vaginal mucosa stained with haematoxylin and eosin (H&E). As in figure 3.11, there are four different areas following the CO₂ fractional laser treatment *SmartXide² V²LR* CO₂. The light microscope does not show significant structural modifications in zone 4. It is possible to see the characteristic scallop-shaped aspect typical of the connective tissue of the vaginal mucosa.

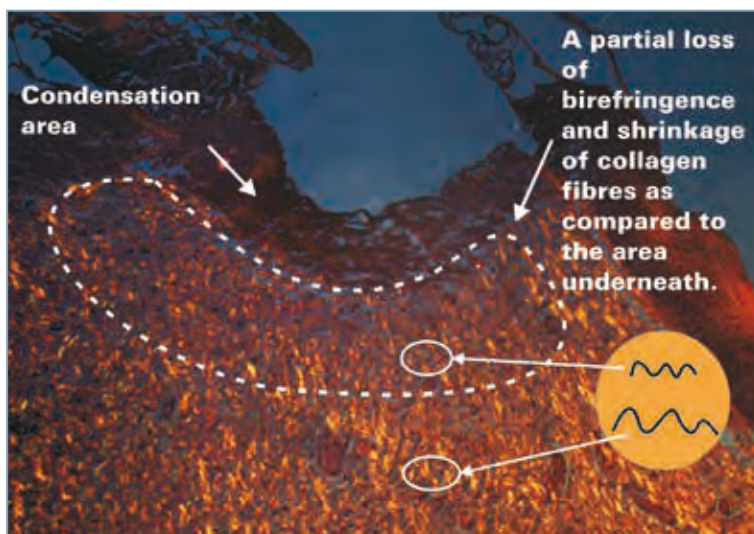

Figure 3.13 – The same section shown in figure 3.12, observed at the polarizing microscope. The condensation band is dark: the collagen, due to denaturation, has completely lost its highly organized structure (loosing of birefringence). In zone 4 there is a wide area, immediately below the denaturation band, with a partial loss of birefringence and a reduction in the diameter of collagen fibres.

The highly organised bundles of collagen fibres which are present in large numbers in the connective tissue are clearly visible with polarized light microscopy. Whereas the epithelium, in which the cells do not contain highly organized structures, appears dark.

Figures 3.12 and 3.13 show the same section of tissue, treated with SmartXide² V²LR laser, observed with traditional optical microscope and polarized light microscope respectively.

By using the polarized light microscope it is possible to confirm that in zone 3 there is denatured collagen, which is collagen that has completely lost its high degree of molecular organization: indeed it appears completely dark, without brightness. If we observe the whole area below the denaturation band we can clearly see, thanks to birefringence, the scallop-shaped bundles of collagen fibres, typical of the connective tissue of the vaginal mucosa. Through a more accurate observation it is however possible to detect a new region which was not easily visible with traditional imaging. Immediately below denatured collagen there is a wide area characterized by a diameter reduction of collagen fibres. This area which apparently had not been affected by laser, was indeed involved although without irreversible damage to its structures.

3.5.2 Transmission Electron Microscopy

Following the aforesaid observations, we analysed different areas of the mucosa using electron microscopy.

Figure 3.14 shows a section of tissue taken from the area affected by collagen denaturation, which corresponds to the zone that showed no birefringence under the polarized light microscope.

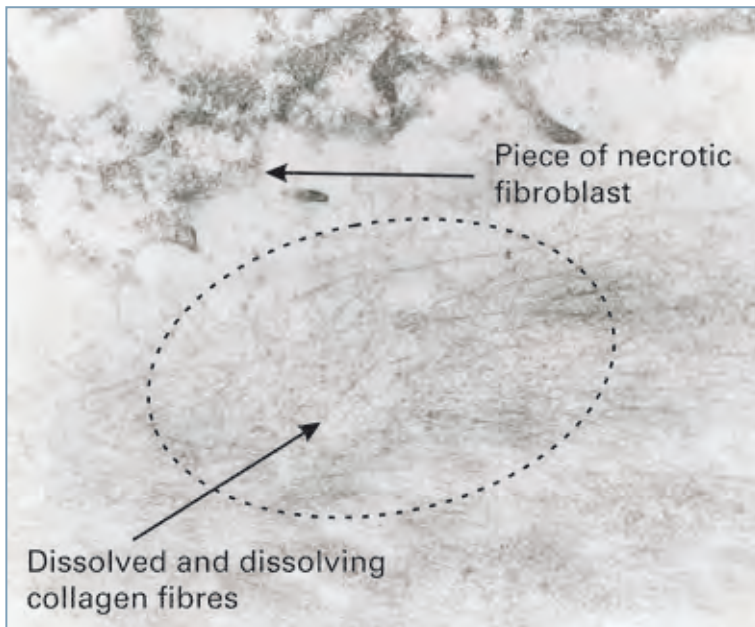


Figure 3.14 – Image of a part of tissue corresponding to the collagen denaturation band, observed at the electron microscope. In the upper side of the image, it is possible to see a part of necrotic fibrocyte or fibroblast (we cannot distinguish between them because of the necrosis). In the centre, numerous dispersed filaments without any organization are observable. This a typical feature resulting from solubilisation of collagen fibrils with the delivery of single molecular filaments (longitudinal view).

On the upper side of the image we observe a portion of necrotic fibroblast or fibrocyte (we cannot distinguish between them because of the necrosis) containing a cytoplasm with no clearly identifiable structure. Structural proteins are indeed very sensitive to thermal effects, much more than collagen which is an extracellular protein. The coagulation of a single protein is enough to stop the internal mechanisms that allow for the survival and functionality of the cell.

In the centre of the image we note solubilised or solubilising collagen fibres with individual scattered filaments. Collagen denaturation causes the solubilisation of its components due to the rupture of covalent bonds that maintain simple molecules in their natural organized state.

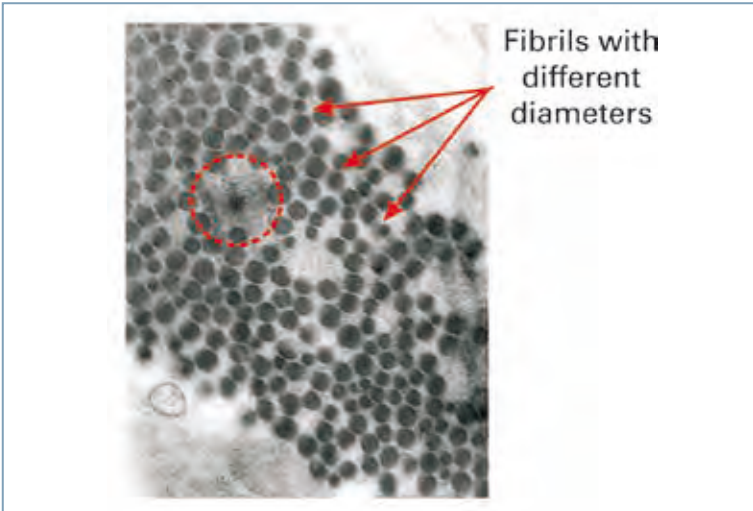


Figure 3.15 – Image of a portion of tissue that corresponds to the collagen denaturation band, observed under the electron microscope. Transversal view of solubilising collagen fibres. It is possible to see that some fibrils have a smaller diameter. In the enclosed area within the dotted line, there are scattered points around what was a collagen fibril. These are the sections of individual filaments that are shed to be later arranged in a disorderly manner.

Figure 3.15 shows the transverse view of still packed collagen fibrils in an early stage of solubilisation. The diameter of fibrils is shrinking and some of them have already broken into individual filamentous molecular components that will later be disorderly dispersed.

In figure 3.16 we can see a section of the mucosa about 500-600 μm below the collagen denaturation band, in the zone that showed birefringence under the polarized light microscope, but where the diameter of collagen fibres is narrower as compared to the normal diameter (as shown in Figure 3.13).

In this image we can also see scattered filaments that are not yet organized but, unlike what we have seen in figure 3.14, the cell in the upper side of the image is not necrotic and shows instead a perfectly preserved membrane and also organelles (rough endoplasmic reticulum and mitochondria) well preserved and active. It is evident that this cell is a fibroblast and not a quiescent fibrocyte.

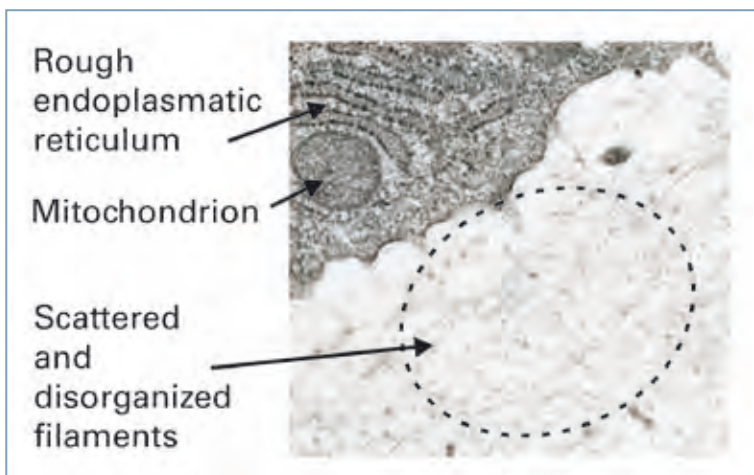


Figure 3.16 – Image of a part of tissue approximately 500-600 μm below the collagen denaturation band, observed at the electron microscope. In the upper side of the image, it is possible to see a cytoplasmic profile of a fibroblast with perfectly preserved plasma membrane and highly organized cytoplasmic organelles. In the lower side, scattered individual filaments are observable.

Given the good conditions of fibroblasts in this zone, we could suppose that the scattered filaments shown in figure 3.16 are not representing solubilised collagen, but are instead new protein filaments produced by the cell above. This is suggested by the ultrastructure of fibroblasts with a well-developed rough endoplasmic reticulum whose cisternae contain an electron dense and fibrillar material, very likely representing the molecular precursors of the matrix components.

To better explain the hypothesis previously stated, we have to examine the metabolic pathways that allow fibroblasts to secrete collagen.

In the general structure of a fibroblast, shown in figure 3.17, we can identify different components. Among them, two organelles are especially important for a better understanding:

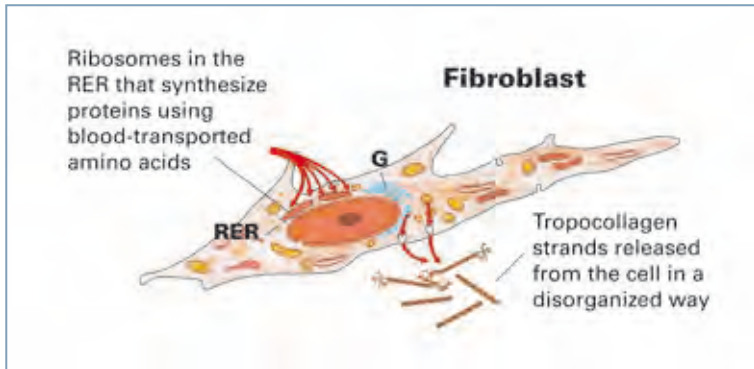


Figure 3.17 – Schematic representation of the metabolic pathways of collagen synthesis in a fibroblast.

1. Rough Endoplasmic Reticulum (RER): is a series of folded membranes that form the so-called cisternae, while the word “rough” refers to the fact that its external surface is rich in ribosomes. Many polyribosomes, on the surface of the RER membranes, are attached on a single mRNA molecule containing the coded information transcription from DNA, so defining as a specific gene expression (translation) the protein to synthesize (collagen or others). Summarizing, the task of ribosomes is to synthesize proteins through a process known as “protein synthesis”. Once the proteins have been formed, they are carried inside cisternae and packed inside a membrane (forming the so-called budding of transition vesicles) in order to be released in the extracellular space, moving to the Golgi apparatus where they will be modified (glycosylation) and delivered into the matrix through exocytosis.
2. Golgi apparatus (G): consists of stacked flat membranes known as cisternae. It can be considered as a centre for production, storage, sorting and shipment, in which the products of the rough endoplasmic reticulum

are modified, stored and sent to the outside of the cells. The transfer of substances from the rough endoplasmic reticulum to the Golgi apparatus is carried out by transport vesicles. With regards to this specific context, it plays a critical role in the modifications and/or synthesis of glycoproteins, polysaccharides (hyaluronic acid and other glycosaminoglycans), and proteoglycans that are released directly by the fibroblasts of the extracellular matrix hence forming the ground substance of the connective tissue.

Thanks to the combined action of different structures, the fibroblasts activate collagen biosynthesis. Through the protein synthesis of the ribosomes of the rough endoplasmic reticulum, molecular chains are formed that fold in groups of three thus creating a triple helix, the procollagen molecules, stabilized by specific chemical bonds. These molecules, through transport vesicles, reach the Golgi apparatus where the glycosilation takes place and here, through secretory vesicles, the molecules are delivered out of the cell where terminal residues are removed transforming procollagen peptides into tropocollagen^[2].

Under suitable environmental conditions, tropocollagen molecules are regularly arranged in parallel lines so as to form fibrils (extracellular fibrillogenesis process). Finally, the fibrils can either be arranged in parallel or undulating lines so as to form fibres and the fibres can, in turn, form bundles (Figure 3.18).

However, the role of the ground substance is crucial in order to make sure that this process is completed in the appropriate way. Only its correct and calibrated composition makes it possible for tropocollagen molecules to aggregate and form a highly organized collagen structure, such as

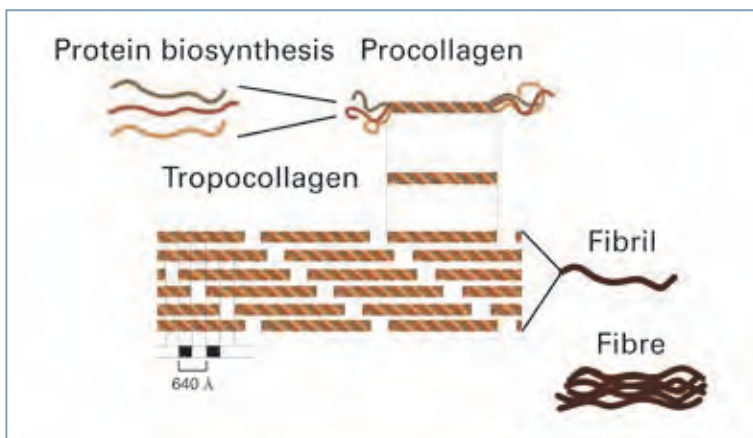


Figure 3.18 – Fibrillogenesis of collagen in the extracellular matrix. Procollagen synthesized by fibroblasts gives rise to tropocollagen which aggregates in a highly ordered spatial organization forming collagen fibrils and fibres.

the fibril. The fibroblast has therefore a double role since it produces both the “building blocks” (tropocollagen molecules) that are necessary to form collagen fibrils and fibres, and the “glue” that is necessary to position and arrange them in the correct way (that is to say the fundamental components of the ground substance: hyaluronic acid, glycosaminoglycans and proteoglycans) (Figure 3.19).

During menopause the mucosa is characterized by the presence of quiescent fibrocytes, instead of fibroblasts, hence it is unable to actively produce hyaluronic acid and other molecules that are needed to form a ground matrix with a suitable level of glycoproteins. The mucosa is dry and less lubricated, less nourished, fragile and susceptible to infections. Due to a low water content in the connective tissue, both nutrients and lymphocytes that reach the lamina propria through blood vessels, have more difficulties in migrating through the extracellular matrix and reaching the epithelium, which is the area attacked by infectious agents.

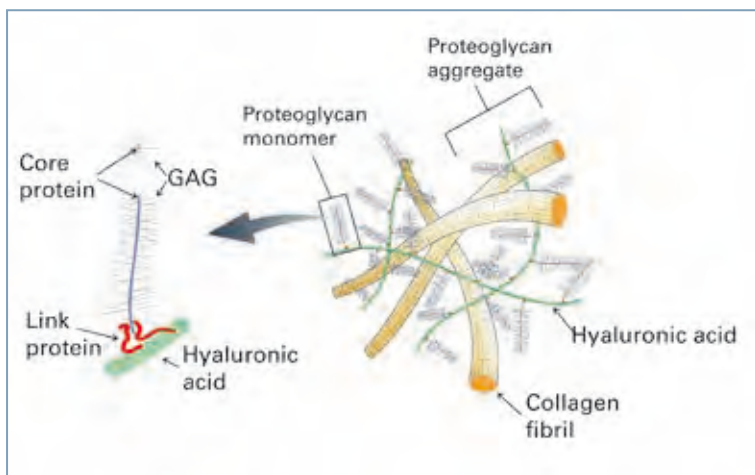


Figure 3.19 – Schematic representation of the three-dimensional structure of the extracellular matrix consisting of a fibrillar component (mainly collagen) and a ground substance.

The purpose of the treatment for vaginal atrophy is to recover and stimulate pre-menopausal metabolic activity through a new synthesis of collagen and also of hyaluronic acid, glycosaminoglycans and proteoglycans. The result is a hydrated turgid mucosa with all the functions typical of a younger and healthier tissue.

According to the aforesaid objectives, we have to see whether it is possible to give better evidence of the activity of the fibroblasts, in spite of the short period of time between treatment and sample fixation. With the help of the electron microscope we analysed images relative to the rough endoplasmic reticulum and the Golgi apparatus in cells located in the area below the denatured collagen.

Figure 3.20 shows in detail the aspect of the rough endoplasmic reticulum of one of these cells.

The cell cytoplasm appears to be particularly rich in cisternae of the rough endoplasmic reticulum. These structures seem to be formed by membranes delimitating the cavity, with numerous ribosomes (responsible for protein synthesis)

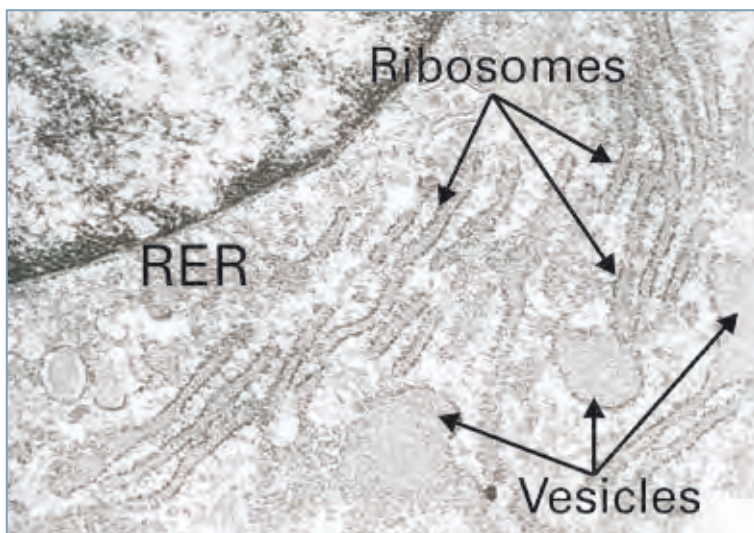


Figure 3.20 –Image of the inside of a fibroblast in the region approximately 500-600 μm below the collagen denaturation band, observed at the electron microscope. The Rough Endoplasmic Reticulum (RER) is well developed with numerous ribosomes bound to the membranes of flat cisternae. Some of these cisternae develop terminal vesicles rich of fine filamentous material.

bound to them. The cisternae of the rough endoplasmic reticulum contain filaments and fluffy material. Unlike the usual laminar aspect, poor in material, which is typical of relatively quiescent cells (fibrocytes), the cisternae are often dilated and contain vesicles rich in microfilaments. This aspect is also associated with morphological features that are typical of active fibroblasts. This suggests a functional metabolic stimulation closely linked with protein synthesis. It is highly probable that the large number of filaments inside the cisternae of the rough endoplasmic reticulum are the procollagen molecular structures, precursors that will be directed to the extracellular matrix to form collagen fibrils and whose generation, via the assembly of tropocollagen molecules, is dependent on the molecular composition of the ground matrix.

Another peculiar aspect observed in the fibroblasts of the samples examined, which can be related to the

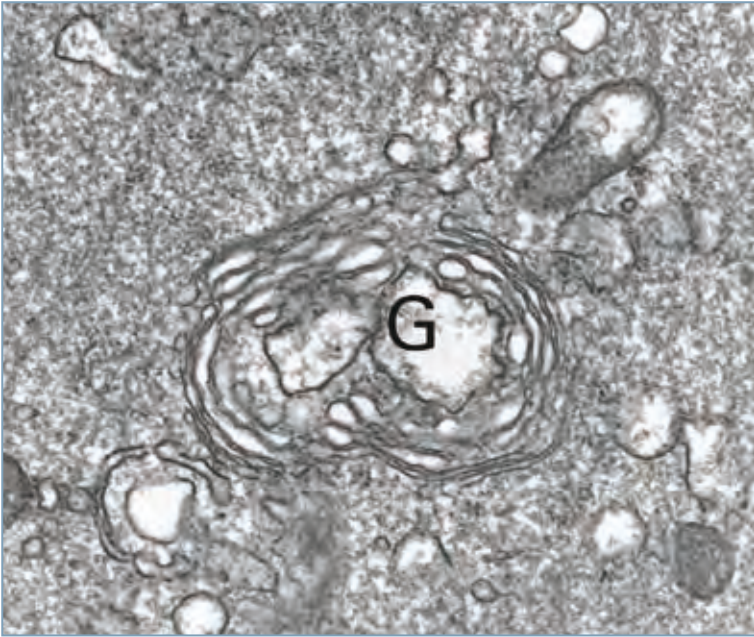


Figure 3.21 – Image of the inside of a fibroblast in the region approximately 500-600 μm below the collagen denaturation band, observed under the electron microscope. The Golgi Apparatus (G) is also well developed. There are vesicles that possibly contain the components that will form the ground matrix.

observations relative to the rough endoplasmic reticulum and to fibroblasts activation in neo-fibrillogenesis, is the extended Golgi apparatus (Figure 3.21), formed by membranes forming smooth and flat cisternae, parallelly arranged one to the other, often dilated with numerous associated vesicles. This peculiar ultrastructural aspect can be related to an intense functional activity directed both at the glycosylation of proteins coming from the RER, and at the synthesis of glycoproteins, glycosaminoglycans and proteoglycans, which form the components of the ground substance.

All the aspects explained above can be ascribed to a condition in which fibroblasts are activated in the synthesis of both proteins (mainly collagen) and molecular components of the ground matrix.

3.5.3 Discussion

Under the experimental conditions of the study presented in this section, the important aspect appears to be the activation of fibroblasts of the vaginal mucosa.

Significant ultrastructural elements, such as the extended rough endoplasmic reticulum with membranes arranged in such a way as to delimit dilated cisternae, rich in ribosomes outside and filaments inside, and the Golgi apparatus with wide cisternae in close relation with a considerable amount of vesicles, are clearly the evidence of an intense protein synthesis by the rough endoplasmic reticulum. Most likely these are the protein precursors of collagen fibres as well as of proteins destined to attach to the polysaccharides of the ground substance so as to form organizations of macromolecules rich in polar sites. The aspect of the Golgi apparatus which shows a significantly increased synthesis of ground substance components and protein glycosilation is closely related to the observations we just made. The correct assembly of tropocollagen molecules into fibre aggregates with high mechanical and physical characteristics - which is crucial to ensure adequate support to the wall of the organ involved in the treatment - depend on their composition.

Biochemical mechanisms at the basis of these phenomena are to be attributed to the thermal effect caused by the CO₂ fractional laser *SmartXide² V²LR*, due to its special emission characteristics which allow for the transfer of the energy load to the mucosa while avoiding excessive localized damage. The wavelength of the CO₂ laser is absorbed by water molecules that are present in large volume in the ground matrix. Water molecules, either free or ion bonded to residues of negative charge of polysaccharides and glycoproteins, register an increase in temperature which

stimulates the activation of a collagen-specific molecular chaperone known as *Heat Shock Protein 47* (HSP47) in the fibroblasts. This promotes the functional activity of fibroblasts with a renewed collagen synthesis.

The data presented herewith concerning the effect of the CO₂ fractional laser *SmartXide² V²LR* shows the efficacy of this method and, above all, allows for a better understanding of cellular and molecular mechanisms that are the foundations of tissue remodelling, resulting in structural improvements which are needed to recover the trophism and full function of vaginal wall support structures.

3.6 PRACTICAL EFFECTS ON VAGINAL ATROPHY-RELATED SYMPTOMS

The first chapter of this book showed how decreased oestrogen levels during menopause are closely linked to alterations in the morphology of vaginal epithelium, reduction of blood flow, vaginal secretion and pH increase due to reduced vaginal lactobacilli. Following the results obtained with the study presented in this publication, it is interesting to focus on the “practical” implications we can expect depending on the structural improvements achieved thanks to the *MonaLisa Touch[®]* treatment.

As already explained in previous paragraphs, restoring the correct composition of the extracellular matrix - where collagen fibres are inside the ground substance with adequate water content - allows for the restoration of the permeability of the connective tissue thus enabling the physiological transfer of various nutrients from capillaries to tissues. When this process is compromised, as it happens with vaginal atrophy, the epithelium – which does not contain vessels – does not receive nutrients,

hence “deteriorates” and becomes thinner, leading to the problems dealt with in chapter 1.

Therefore, it is clear that the effect produced by the *MonaLisa Touch*® technology can benefit even the epithelium, restoring epithelial cell trophism. Also, in the blood, besides nutrients, there is still a certain level of oestrogens that, albeit lower compared to pre-menopause, are produced by other organs of the female body. By restoring the correct amount of blood supply in the lamina propria and with an increase of ground matrix permeability, this contribution, however small, reaches its destination to the epithelium.

Pertaining to vaginal “dryness,” this is due to the reduced general trophism resulting from a diminished peripheral blood flow and, above all, to a lower level of hydration caused by the reduced activity in fibroblasts, which lead to a less turgid – since less hydrated – ground matrix. Thanks to a correct composition of the ground substance produced by the fibroblasts, the water brought to the capillaries can rehydrate the whole vaginal mucosa tissues. Other problems caused by vaginal dryness, such as itching or burning sensation, are solved by restoring the correct hydration level of the mucosa.

Reduced vaginal secretion, often associated with dyspareunia (painful sexual intercourse), requires a more thorough analysis. Over the years, many researchers postulated theories concerning the main source of vaginal lubrication. Consideration was given to the role of the greater vestibular glands (or Bartholin’s glands) and Skene’s glands, located on the external genitals, which provide secreted mucus to the labia minora. Studies conducted by Master and Johnson^{[3],[4]}, show instead that lubrication is due to secretions produced deeper within the vagina.

Today, it can be said that vaginal lubrication is mediated by neuro-vascular and biochemical phenomena that are only partially understood^[5]. It is determined by the presence of fluid generated by the combination of secretions from different structures of the genital apparatus. The main component is vaginal transudate which results from the slow blood outflow through the capillaries that supply water and nutrients to the vaginal epithelium^[6]. This allows plasma to be transferred from the vascular bed, through the epithelium, and to the vaginal inner surface. During sexual arousal, the blood flow into the vagina rapidly increases as a consequence of the parasympathetic innervation provided by the pelvic splanchnic nerves^[7]. This in turn causes an increase in the transudate present between the vaginal epithelial cell which saturates the retention capacity and floods into the vaginal lumen. In the presence of vaginal atrophy, the amount of vaginal transudate drops. If we take into account the same mechanisms presented to explain the restoration of the epithelium, it is easy to imagine how the *MonaLisa Touch*[®] treatment can stimulate the production of vaginal transudate. In regards to vestibular glands, the role of which is widely debated, they will benefit from the treatment of the vaginal mucosa as they are adjacent to it. Besides, a specific local treatment by means of the CO₂ fractional laser SmartXide² V²LR, could stimulate functional recovery just as it happens with vaginal mucosa.

Finally, let's see what happens with an increased pH. In women of reproductive age, during the follicular phase of the ovarian cycle, the epithelial cells of the vagina synthesize and store glycogen as they migrate towards the surface from which they shed as a result of exfoliation (Figure 3.22). The exfoliation rate increases in the second part of the cycle and the glycogen released from exfoliated cells is used

by vaginal lactobacilli which produce lactic acid making the vagina acidic, thus preventing pathogen colonization. With the menopause, the epithelium and the underlying lamina propria are developing atrophy: glycogen in the epithelial cells decreases and consequently the lactobacilli that need glycogen to thrive - and are responsible for maintaining the pH acidic - also decrease. Once again we can make some remarks on the restoration of trophism of the vaginal mucosa, which leads to an increase in glycogen levels and can favour the colonization of vaginal lactobacilli as well as vaginal acidity.

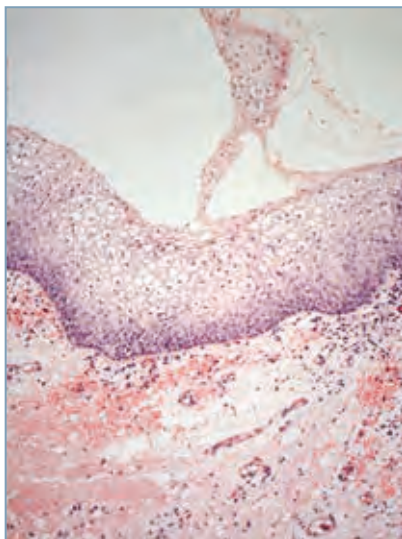


Figure 3.22 – Histological preparation of vaginal mucosa stained with haematoxylin and eosin (H&E). Vaginal mucosa in reproductive age. The epithelial cells rich in glycogen shed from the surface. [Courtesy of Prof. A. Calligaro – University of Pavia].

3.7 CO₂ LASER IN VAGINAL ATROPHY TREATMENT

On the basis of the innovative results attained with the preliminary study illustrated in the previous paragraphs, we planned a new trial on 50 patients suffering from vaginal atrophy, in order to assess the outcome of the *MonaLisa Touch*[®] treatment over a longer period of time and to quantify improvements.

According to inclusion criteria set for the study, the selection of patients were based on the following characteristics and/or symptoms:

- Symptoms of VVA (vaginal dryness and/or dyspareunia rated as moderate/severe most bothersome symptoms);
- Age > 50 years;
- Absence of menstruation for ≥ 12 months;
- Not responding/being unsatisfied with previous local estrogen therapies.

The exclusion criteria were follows:

- Use of any hormone replacement therapies (either systemic or local) within the 6 months prior to inclusion in the study;
- Use of vaginal moisturizers, lubricants or any other local preparation within the 30 days prior to inclusion in the study;
- Acute or recurrent urinary tract infections;
- Active genital infections (e.g. herpes genitalis, candida);
- Prolapse staged $\geq II$ according to the *POP-Q (Pelvic Organ Prolapse Quantification system) designed by the ICS (International Continence Society)*;
- Previous reconstructive pelvic surgery;
- Any serious disease or chronic condition that could interfere with study compliance;
- Psychiatric disorders precluding informed consent.

A cycle of three treatments of the vaginal walls was performed using the fractional CO₂ laser system SmartXide², by introducing probes designed for this specific purpose (thanks to the scanner system Hi-Scan V²LR), on women of menopausal age with overt vaginal atrophy. The work consisted in recruitment, follow-up, and data collection

after each of the four scheduled sessions and two interim analyses, one in September 2012 and one in May 2013.

The protocol used is the one that has proven to be more effective in the preliminary study presented in paragraph 3.5. Time points of the study were at baseline (T1), at week 4 (T2), at week 8 (T3), and at week 12 (T4), after 4 weeks from the last laser application. Histological and microstructural examinations were carried out on 5 patients before (basal conditions) and one or two months after the first treatment.

For clinical assessment, objective and subjective tools were used, so as to compare the patient's basal conditions with those after each follow up. More specifically:

- A visual analogue scale (VAS), ranging from 1 to 10, for all vaginal atrophy symptoms (laxity, dryness, irritation or itching, dyspareunia);
- The Vaginal Health Index (VHI) proposed by G. Bachmann^{[8],[9]}, which includes the assessment of the different signs of vaginal atrophy and assigns a final grading;
- The PISQ-12 (*Pelvic Organ Prolapse/Urinary Incontinence Sexual Function Questionnaire*) to assess the sexual function of women with pelvic organ prolapse and/or urinary incontinence;
- Measurement of vaginal pH;
- A generic questionnaire on the quality of the patient's life (SF12);
- A Likert^[10] scale defined as Patient Perception of Improvement to assess the patient's perception of improvement following treatment.

3.7.1 Evaluation of clinical results

With regard to the objective evaluation, we analysed the variation in the mean values for the overall Vaginal Health Index score (Table 3.1).

Score*	Overall elasticity	Fluid secretion type and consistency	pH	Epithelial mucosa	Moisture
1	None	None	≥ 6.1	Petechiae noted before contact	None, mucosa inflamed
2	Poor	Scant, thin yellow	5.6-6.0	Bleeds with light contact	None, mucosa not inflamed
3	Fair	Superficial, thin white	5.1-5.5	Bleeds with scraping	Minimal
4	Good	Moderate, thin white	4.7-5.0	Not friable, thin mucosa	Moderate
5	Excellent	Normal (white flocculent)	≤4.6	Not friable, normal mucosa	Normal

Table 3.1: Gloria Bachman's Vaginal Health Index (VHI). *: Lower score corresponds to greater urogenital atrophy.

The analysis does not include changes in vaginal acidity (pH), as the litmus test systems proved to be inadequate for the task. Mean values for the VHI in patients who completed the study changed as follows: 8.6, 12.4, 14.5 and 14.5 again at baseline, and after each of the three individual treatments respectively. This trend corroborates the trophic changes in the vaginal canal in patients treated.

Table 3.2 and figure 3.23 show the changes in average values for single symptoms of vaginal atrophy at baseline and after each of the three individual treatments:

	Baseline	After 1 SESSION	After 2 SESSIONS	After 3 SESSIONS
Vaginal Burning	5.1	2.3	1.9	0.8
Vaginal Itching	4.8	1.9	1.9	0.7
Vaginal Dryness	8.4	4.4	3.4	2
Dyspareunia	8.5	4.1	3	2.4
Vaginal Laxity	1	0.6	0.4	0.1

Table 3.2: Average VAS values for main symptoms of vaginal atrophy.

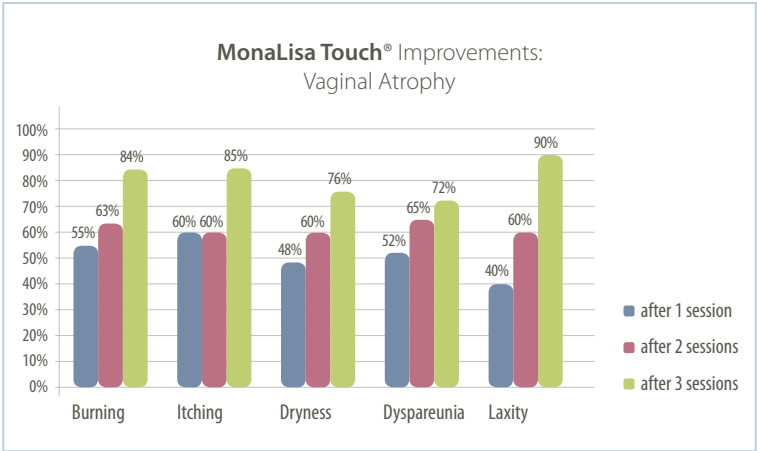


Figure 3.23: Improvement (%) for the main symptoms of vaginal atrophy after 3 *MonaLisa Touch®* sessions.

Urinary symptoms changes, in average values, at baseline and after three treatments are showed in the table 3.3 and in the figure 3.24:

	Baseline	After 3 SESSIONS
Dysuria	1.3	0.4
Urinary urgency	2.6	0.8
Urge incontinence	1.6	0.7
Stress Urinary Incontinence	3.1	1.3

Table 3.3: Average VAS values for main urinary symptoms, before and after 3 *MonaLisa Touch*® treatments.

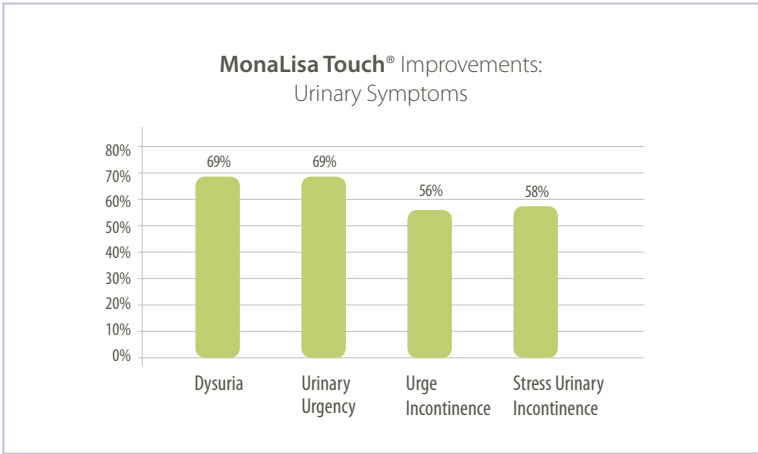


Figure 3.24: Improvement (%) for the main symptoms of urinary incontinence after 3 *MonaLisa Touch*® sessions.

The present pilot study demonstrated for the first time that *MonaLisa Touch*® laser treatment is effective for the treatment of vaginal atrophy in postmenopausal women.

Indeed, the results of the current study showed that a treatment cycle of three laser applications significantly improved most bothersome symptoms of uro-genital atrophy and scores of vaginal health at 12-week follow-up. A positive effect on symptoms was already evident after the first laser application and further increased at the end of the study period, in which even a significant improvement of both physical and mental scores of quality of life was observed in comparison with baseline.

3.7.2 Evaluation of Histological Results (both Microscopical and Ultrastructural Examinations)

As mentioned in the previous section, histological examinations were carried out on 5 patients before and one and two months after the first treatment.

Figures 3.25, 3.26, 3.27 and 3.28 compare images relative to the vaginal mucosa of a patient before the beginning of the treatment and one month after the first session with the *MonaLisa Touch*® procedure.

The assessment of these histological examinations shows that after treatment:

- the mucosa is well nourished with extended three dimensional papillae rich in blood vessels;
- the glycogen in the epithelial cells is clearly increased and is present in a larger amount as compared with the initial condition;
- the extracellular matrix (collagen fibres and ground substance) has increased with numerous fibroblasts that can be clearly identified.

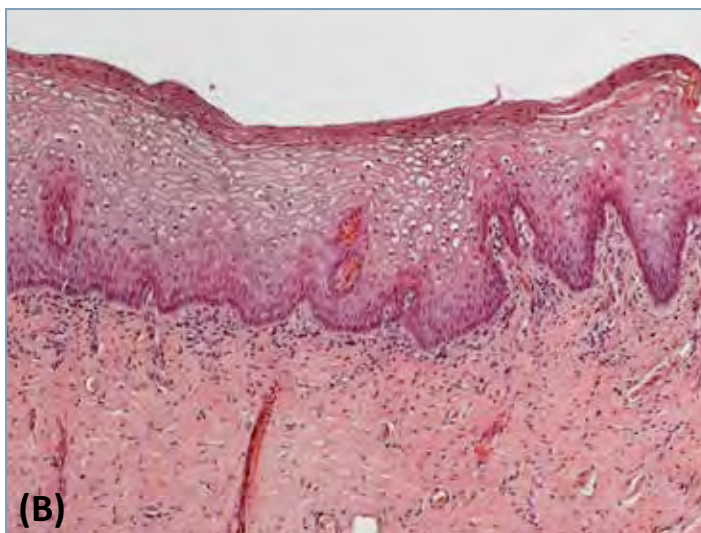
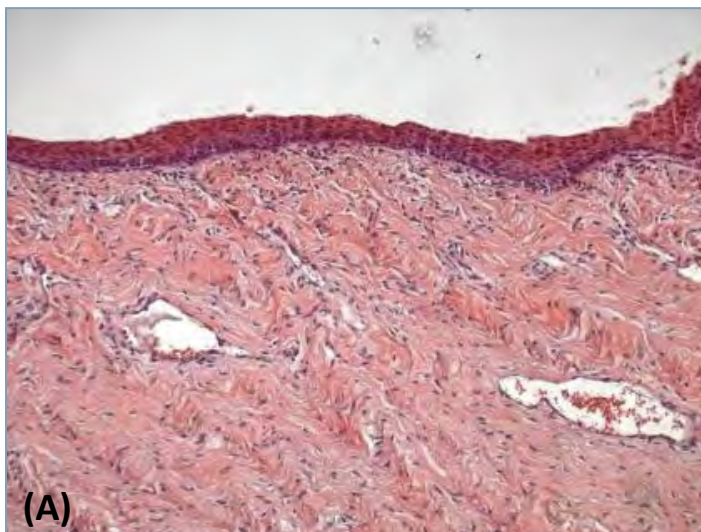


Figure 3.25 – Histological preparation of a section of the vaginal mucosa stained with haematoxylin and eosin (H&E). (A): Vaginal mucosa in the basal condition. This morphological picture indicates vaginal atrophy at an advanced stage with an epithelium formed by few cell layers and no papillae. (B): Vaginal mucosa of the same patient one month after the first session with the *MonaLisa Touch*® treatment. The much thicker epithelium and the larger diameter of epithelial cells rich in glycogen, demonstrate the restored metabolic trophism and dynamics of the whole epithelium.

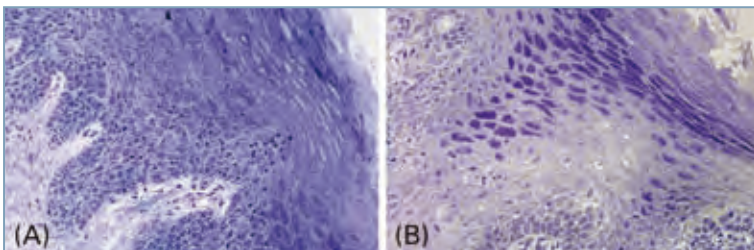


Figure 3.26 – Histological samples fixed in a paraformaldehyde/glutaraldehyde solution, included in epoxy resin and stained with toluidine blue. (A): Vaginal mucosa in the basal condition. (B): Vaginal mucosa of the same patient one month after one session with the *MonaLisa Touch*[®] treatment. There is a clear storage and release of glycogen in the epithelium of the mucosa. The absence of leukocytes in the epithelium shall also be pointed out.

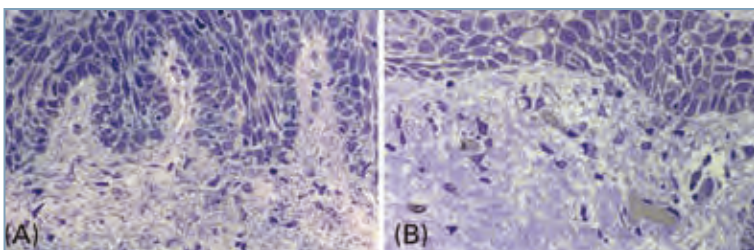


Figure 3.27 – Histological samples fixed in a paraformaldehyde/glutaraldehyde solution, included in epoxy resin and stained with toluidine blue. (A): Vaginal mucosa in the basal condition. (B): Vaginal mucosa of the same patient one month after a session with the *MonaLisa Touch*[®] treatment. There is an increase in the matrix of the connective tissue (fibres and ground substance) with a large presence of fibroblasts, of vessels and fibroblasts.

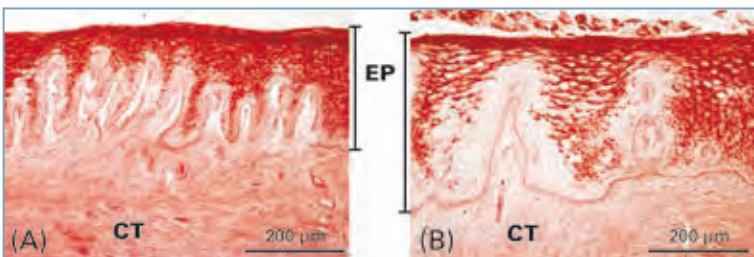


Figure 3.28 - Histological preparation of a section of the vaginal mucosa stained with Periodic Acid - Schiff reagent (PAS) method. (A): Vaginal mucosa in the basal condition. The most superficial layers of the epithelium has small and closely compacted cells with absence of shedding. (B): Vaginal mucosa of the same patient one month after a session with the *MonaLisa Touch*[®] treatment. It is possible to observe a much thicker epithelium (EP) and wide columns of large epithelial cells rich in glycogen (red). In the most superficial layers large detaching cells rich in glycogen are visible. Comparing both pictures, after the treatment a much better organized connective tissue (CT) both in lamina propria and in the core of papillae is also observable.

N.B.: The images in figure 3.25 show the results from one of the five patients who allowed us to take a sample of vaginal mucosa tissue samples for the histological investigation. Appendix A compares the histologies, before and after initial treatment for all 5 patients analysed.

As illustrated in section 3.5.2, the second study involved a thorough investigation of the histological samples under the electron microscope. The aim was to confirm the changes envisaged in the preliminary study by comparing the images at baseline with those taken two months after the beginning of treatment. The figures below show the results.

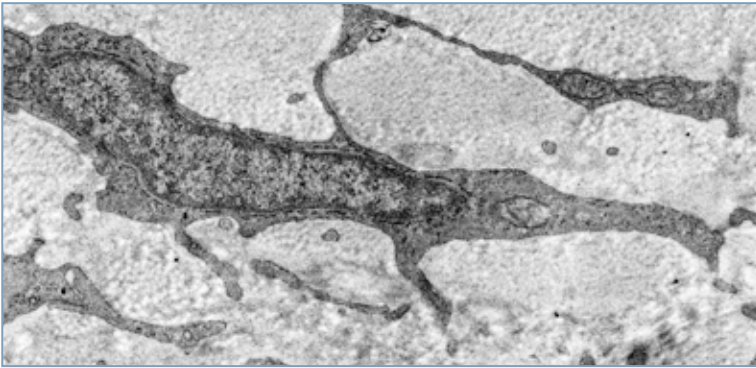

Figure 3.29 - Transmission electron microscopy. Fibrocyte from atrophic vaginal mucosa before treatment.

Figure 3.29 shows a fibrocyte from atrophic vaginal mucosa before treatment. The cell body of the fibrocyte, containing the nucleus, is very small and branches off into thin cytoplasmic extensions that are interspersed between the bundles of collagen fibres in the extracellular matrix and form close relationships with cytoplasmic extensions from other fibrocytes. This creates a “static” situation in which the structural and functional turn-over of the matrix is greatly reduced or completely absent. Note the small size of the cell body and the reduced thickness of the cytoplasmic processes, which are extremely poor in organelles. Profiles of the rough endoplasmic reticulum

(where constitutive protein synthesis of collagen fibers and proteins associated with the molecular components of the amorphous substance takes place) are represented very little or none, as well as the Golgi complex. Ribosomes can be seen adhering to the outer nuclear membrane, with scattered ribosomes in the cytoplasm, mostly single and rarely associated into polyribosomal complexes. The nucleus is compact, characterized by its small size and by a relatively high electron density (heterochromatin = condensed and largely functionally or transcriptionally inactive DNA). From the fibrocytes observed none of the nucleolus was possible to visualize.

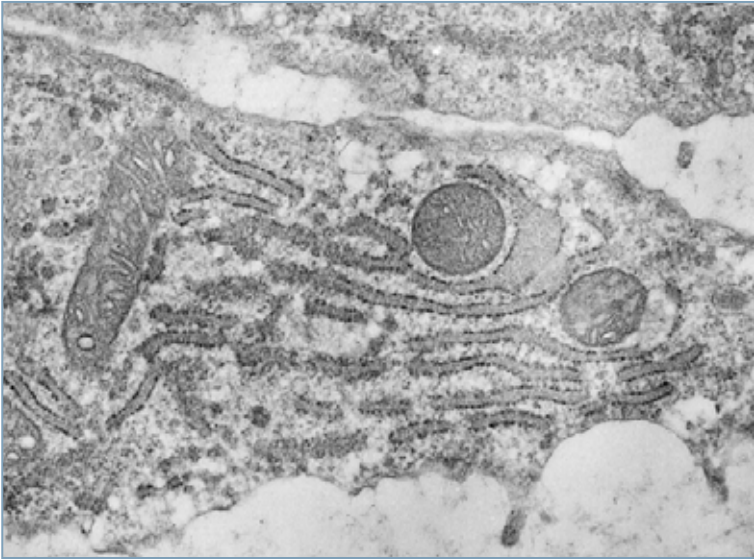

Figure 3.30 -Transmission electron microscopy. Cytoplasmic profile of a fibroblast from vaginal mucosa of the same patient showed in the figure 3.29, one month after the second *MonaLisa Touch*® session.

Figure 3.30 shows a fibroblast wide cell body in the lamina propria of atrophic vaginal mucosa, in the same patient of figure 3.29, one month after the second treatment session. A lot of RER profiles, some dilated and containing a finely

filamentous material (molecular precursors of collagen fibres), are visible. Four mitochondria rich of cristae are also observable.

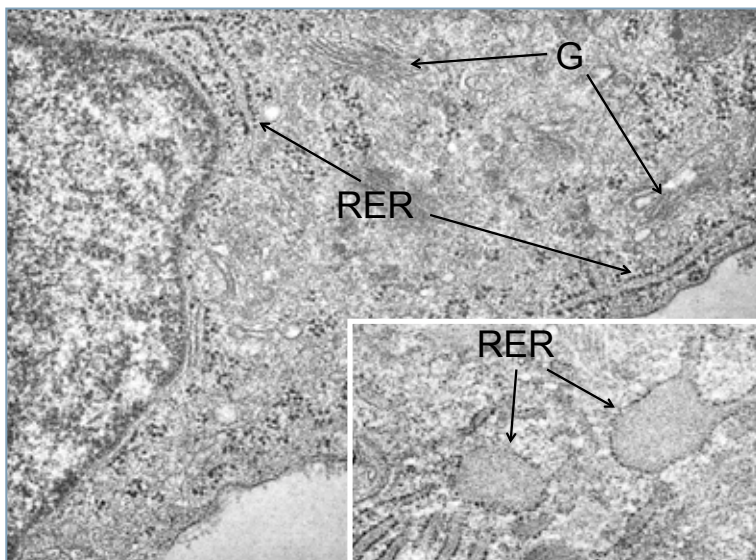


Figure 3.31 - Transmission electron microscopy. Ultrastructure of an activated fibroblast with a well represented Golgi apparatus and a Rough Endoplasmic Reticulum with dilated cisternae (inset). This image refers to the atrophic vaginal mucosa one month after the second *MonaLisa Touch*® treatment session.

Figure 3.31 shows the ultrastructure of a typical activated fibroblast in a patient one month after the second *MonaLisa Touch*® treatment session. The electron micrograph is showing characteristic features: a wide cell body with well visible cisternae of the rough endoplasmic reticulum (RER), often dilated forming vesicles (inset), and a well represented Golgi apparatus (G).

The nucleus (left) shows a low electron density, due to the dispersion of chromatin (euchromatin) facilitating a transcriptional activity related to the synthesis on the RER of the molecular precursors of collagen.

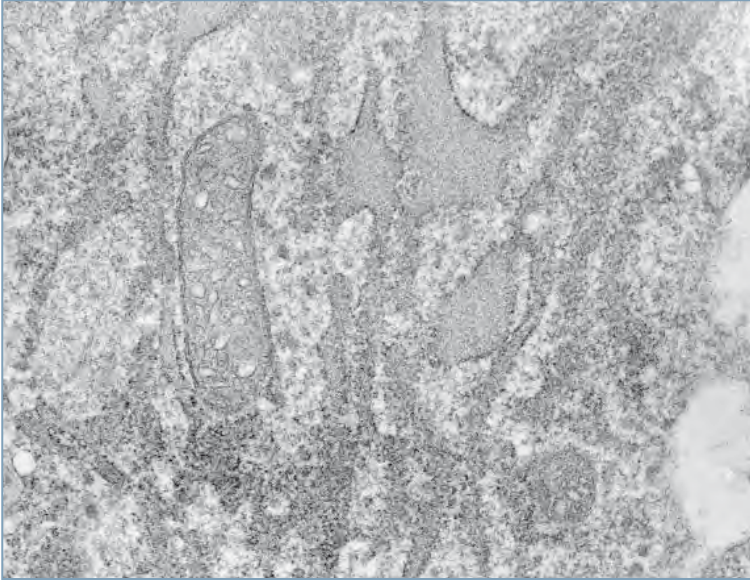


Figure 3.32 -Transmission electron microscopy. Interior of a fibroblast from the vaginal mucosa one month after the second *MonaLisa Touch*® treatment session with CO₂ laser.

Finally, figure 3.32 illustrates a detail of the interior of another fibroblast from the vaginal mucosa one month after the second *MonaLisa Touch*® treatment session. The high-magnification electron micrograph shows:

- the extent of the RER;
- the presence, in the membrane-delimited cisternae with adherent ribosomes, of fine filamentous structures (the molecular precursors of collagen);
- the presence of highly dilated cisternae covered by polyribosomes, with their membrane in direct continuity, with the membrane of confluent rough endoplasmic reticulum profiles.

3.8 MONALISA TOUCH®: A TECHNIQUE IN CONSTANT EVOLUTION

The exciting findings described in the previous sections were the starting point for us to explore this method's true potential. Over the past two years, the *MonaLisa Touch*® treatment has established itself at global level (particularly in Europe, Russia, Brazil, Mexico, Australia, Korea, China and the USA) with over 850 SmartXide² laser systems sold (as of April 2015) to hospitals, universities and private centres. The number of treated patients now exceeds hundreds of thousands and word of mouth has been spreading on social media networks and blogs.

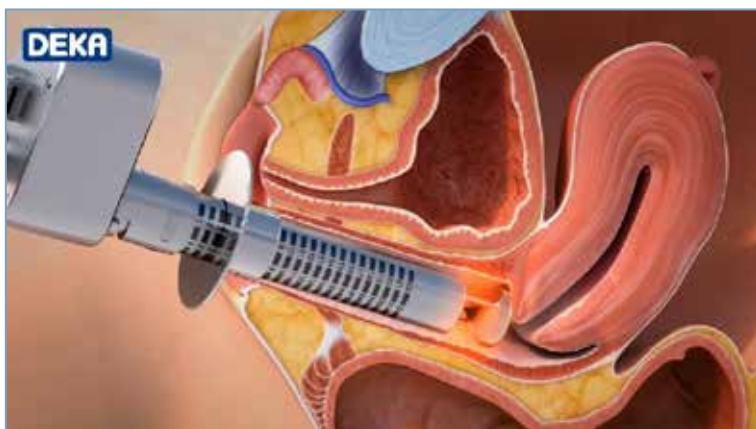

Figure 3.33: *MonaLisa Touch*® vaginal full-angle probe emitting the laser energy in a 360° angle in one time.

To this date, *MonaLisa Touch*® is the only method that have been written up in peer-reviewed journals^{[11]-[16]} (see Appendix B), underlying the importance that DEKA has always given to scientific research.

Originally developed to solve postmenopausal vaginal atrophy-related problems, *MonaLisa Touch*® is proving to be extremely useful and effective in several other situations.

With all its associated issues, atrophic vaginitis is not in fact linked exclusively to the natural ageing process. Urogenital atrophy is closely linked to the reduction in oestrogen synthesis that can occur at various times during a woman's life, such as:

- Early menopause, coinciding with a loss of activity before the age of 40. This condition can occur spontaneously or may be induced for a bilateral oophorectomy procedure or by drug- or radiation-induced ovarian suppression. Whereas spontaneous premature menopause can usually be treated with hormone therapy, this is strongly discouraged in cancer patients who are in menopause due to iatrogenic causes.
- Premature ovarian failure (POF) which may be a transient condition with irregular ovarian activity that may last for years. When POF becomes a permanent condition, it is equivalent to early menopause. Its causes are not always clearly identifiable, and may be of different origin (genetic/hereditary, systemic, iatrogenic or due either to autoimmune diseases, or to viral or bacterial infections). Even a poor lifestyle, with bad eating habits bordering on anorexia, can cause malfunction of the ovaries in young women, associated with chronic oestrogen deficiency.
- Postpartum, especially when breastfeeding. The condition is transient, but can create considerable discomfort, with both physical and psychological consequences for many women and their partners.

In addition to remedying atrophy-related problems, *MonaLisa Touch*® is now also used for:

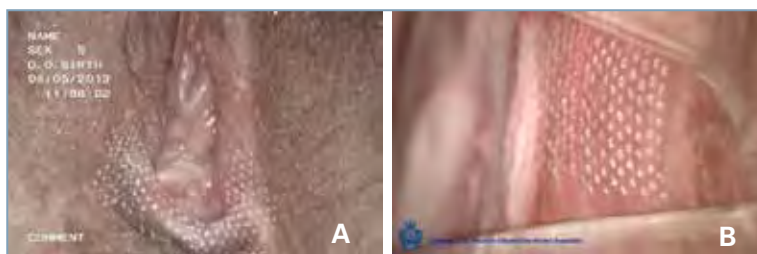


Figure 3.34: Vulva (A) and vagina (B) appearance immediately after *MonaLisa Touch*® treatment. Observe the DOTs on the mucosa without any reddening or bleeding. [Courtesy of M. Filippini, M.D. and M. Farinelli, M.D. San Marino State Hospital, San Marino].

- treating patients with dyspareunia caused by perineal trauma following a spontaneous vaginal, episiotomy-assisted or instrumental delivery;
- non-surgical treatment of vaginal laxity;
- mild urinary incontinence.

As shown in figure 3.35, there are several different handpieces available, allowing the vaginal canal, the vaginal opening, and the vulvar and perineal areas to be treated quickly, safely and effectively, tailoring the treatment to the individual patient's needs.



Figure 3.35: The full range of available probes for HiScan V³LR. Simply changing the probe, the scanner can be easily adapted to all patient's needs. (A): Full-angle vaginal probe emitting the laser energy in a 360° angle in one time. A single-use version will be ready in due course. (B): Single-mirror closed 90° vaginal probe. 2 versions are available with different diameter. (C): Single-mirror open 90° vaginal probe. (D): external terminal for the treatment of vulvar and perineal area.

3.8.1 Conclusions

The *MonaLisa Touch*® procedure can no longer be regarded as experimental, as its diffusion around the world is now complete and has already earned itself a place as one of the possible remedies for the consequences of vulvovaginal atrophy, regardless of its cause.

3.9 REFERENCES

1. Gaspar A, Addamo G, Brandi H. *Vaginal Fractional CO₂ Laser: A Minimally Invasive Option for Vaginal Rejuvenation*. Am J Cosm Surg; September 2011, Vol. 28, No. 3, pp. 156-162.
2. Stephens DJ. *Cell biology: Collagen secretion explained*. Nature vol. 482, 474–475 (23 February 2012).
3. Masters WH. *The sexual response cycle of the human female: vaginal lubrication*. Ann N. Y. Acad Sci 1959; 83:301.
4. Masters WH, Johnson V. *Human sexual response*. Little, Brown & Co. Boston, 1966.
5. Graziottin A, Rovei V, Scarselli GF. *Fisiologia della lubrificazione vaginale*. In: Jannini E.A. Lenzi A. Maggi M. (Eds), *Sessuologia Medica. Trattato di psicosessuologia e medicina della sessualità*. Elsevier Masson, Milano, 2007, pp. 117-119.
6. Giraldi A, Levin R. *Vascular physiology of female sexual function*. In: Goldstein I et al. (Eds), *Women's sexual function and dysfunction. Study, diagnosis and treatment*. Taylor & Francis, London, 2006, pp. 174-180.
7. Giuliano F, Rampin O, Allard J. *Neurophysiology and pharmacology of female genital sexual response*. J Sex Marital Ther 2002, 28(Suppl 1): 101-121.

8. Bachmann G. *Urogenital ageing: an old problem newly recognized*. Maturitas. 1995 Dec;22 Suppl:S1-S5.
9. Bachmann GA. *A new option for managing urogenital atrophy in postmenopausal women*. Contemp Obstet Gynecol 1997; 42: 13-28.
10. Likert R. *Technique for the measure of attitudes*. Arch. Psycho., Vol. 22 N. 140. (1932).
11. S. Salvatore et al. *Histological study on the effects of microablative fractional CO₂ laser on atrophic vaginal tissue: an ex vivo study*. Menopause 2015 Jan 20. doi: 10.1097/GME.0000000000000401. [Epub ahead of print]
12. N. Zerbinati et al. *Microscopic and ultrastructural modifications of postmenopausal atrophic vaginal mucosa after fractional carbon dioxide laser treatment*. Lasers Med Sci 2015 Jan, Vol. 30, No. 1:429-36. doi: 10.1007/s10103-014-1677-2. Epub 2014 Nov 20.
13. A. Perino et al. *Vulvo-vaginal atrophy: A new treatment modality using thermo-ablative fractional CO₂ laser*. Maturitas 2014 Dec 25. doi: 10.1016/j.maturitas.2014.12.006. [Epub ahead of print]
14. S. Salvatore et al. *Sexual function after fractional microablative CO₂ laser in women with vulvovaginal atrophy*. Climacteric 2014 Dec 16. doi:10.3109/13697137.2014.975197 [Epub ahead of print]
15. S. Salvatore et al. *Microablative fractional CO₂ laser improves dyspareunia related to vulvovaginal atrophy: a pilot study*. Journal of Endometriosis and Pelvic Pain Disorders 2014. DOI:10.5301/je.5000184. Epub 2014 Jun 20.
16. S. Salvatore et al. *A 12-week treatment with fractional CO₂ laser for vulvovaginal atrophy: a pilot study*. Climacteric Aug 2014, Vol. 17, No. 4:363-369. doi: 10.3109/13697137.2014.899347. Epub 2014 Jun 5.

APPENDIX A

Complete Before & After Histological Results.

Histological preparation of vaginal mucosa sections stained
with haematoxylin and eosin (H&E)

Courtesy of Prof. A. Calligaro.

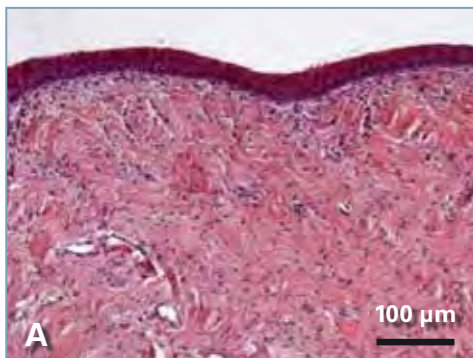
Professor of Histology and Embryology at the University of Pavia, Italy

Patient no.1 – sequence A:

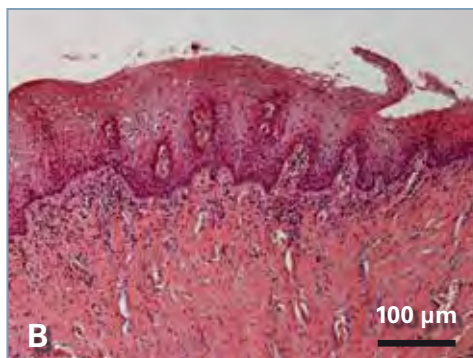
Age: 54

Age at menopause: 44 years old

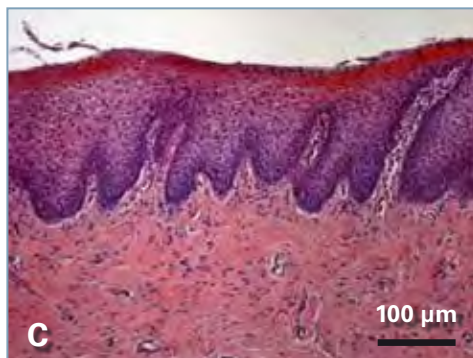
Note: the patient has never used HRT



(A) Vaginal mucosa in the basal condition with a thinner epithelium typical of atrophic vaginitis.



(B) The same patient one month after the 1st *MonaLisa Touch*® session. It is evident the thicker epithelium of the mucosa.



(C) The same patient one month after the 2nd *MonaLisa Touch*® session. It is possible to observe a further thickening of the mucosa epithelium.

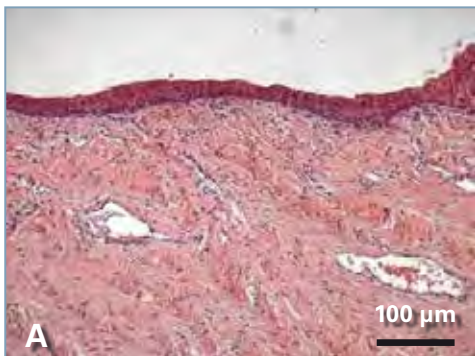
Pictures magnification 100x

Patient no.1 – sequence B:

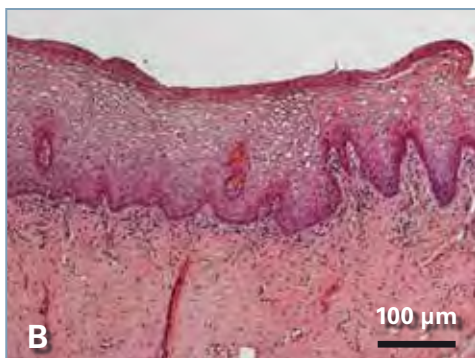
Age: 54

Age at menopause: 44 years old

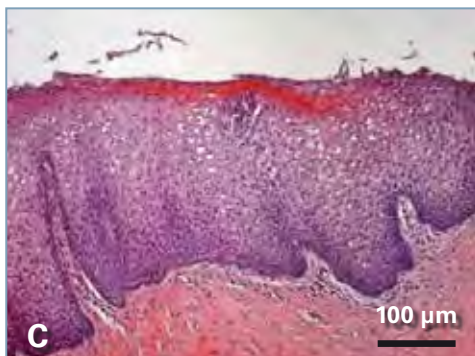
Note: the patient has never used HRT



(A) Vaginal mucosa in the basal condition with a thinner epithelium typical of atrophic vaginitis.



(B) The same patient one month after the 1st *MonaLisa Touch*® session. It is evident the thicker epithelium of the mucosa.



(C) The same patient one month after the 2nd *MonaLisa Touch*® session. It is possible to observe a further thickening of the mucosa epithelium.

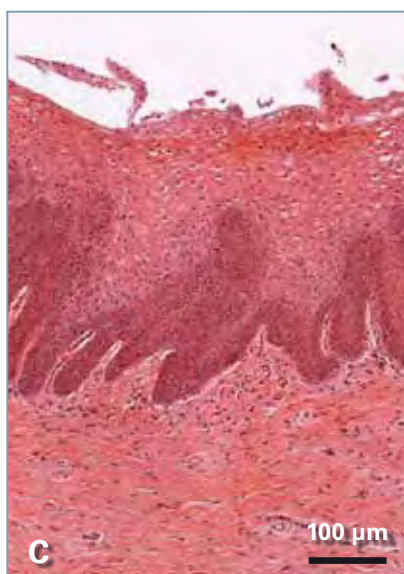
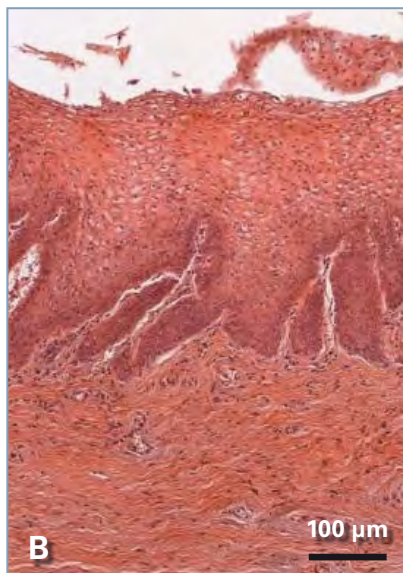
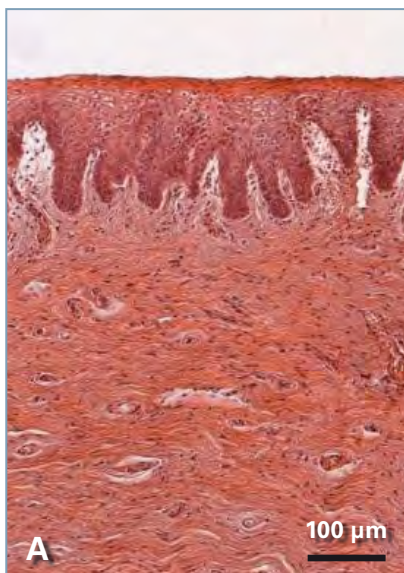
Pictures magnification 100x

Patient no.2:

Age: 59

Age at menopause: 48 years old

Note: The patient has never used HRT



(A) Vaginal mucosa in the basal condition. It is possible to see a thinner epithelium and the presence of papillae. This morphological picture indicates vaginal atrophy at an early stage, gradually evolving towards a condition characterized by an epithelium formed by few cell layers and no papillae.

The same patient one month after the 1st *MonaLisa Touch*® session **(B)** and the 2nd session **(C)**. The much thicker epithelium and shedding of numerous big cells from the free surface, together with the larger diameter of epithelial cells rich in glycogen, demonstrate the restored metabolic trophism and dynamics of the whole epithelium.

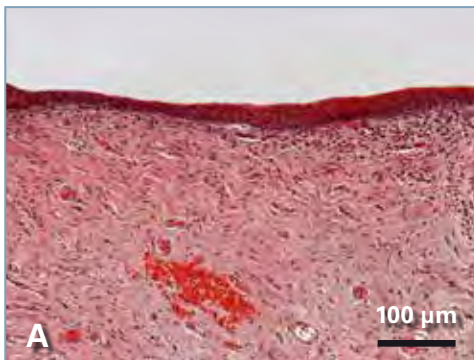
Pictures magnification 100x

Patient no.3:

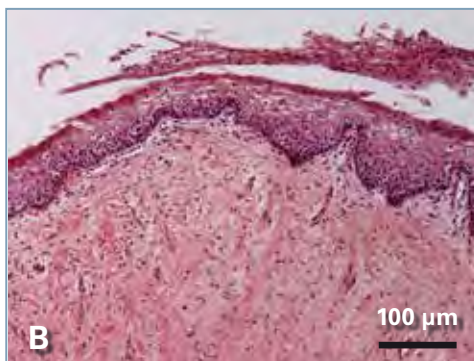
Age: 55

Age at menopause: 44 years old

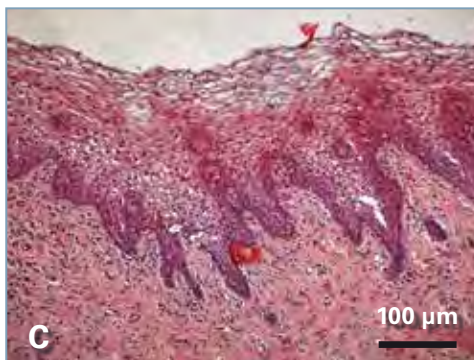
Note: The patient has never used HRT. Breast cancer familiarity.



(A) Vaginal mucosa in the basal condition with a thinner epithelium typical of atrophic vaginitis.



(B) The same patient one month after the 1st *MonaLisa Touch®* session.



(C) The same patient one month after the 2nd *MonaLisa Touch®* session. It is possible to observe an evident thickening of the mucosa epithelium with the presence of newly formed papillae of connective tissue.

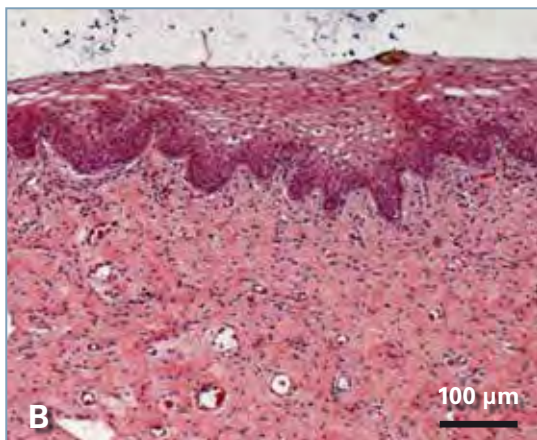
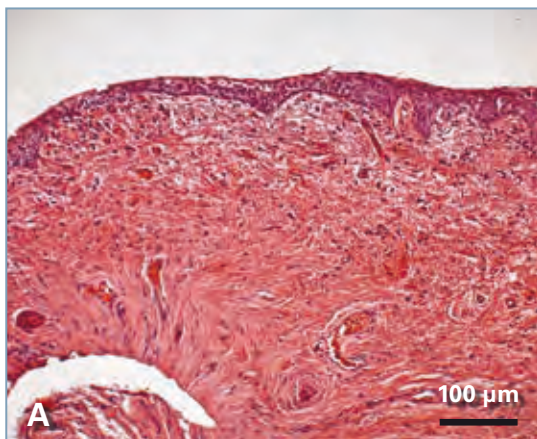
Pictures magnification 100x

Patient no.4:

Age: 63

Age at menopause: 49 years old

Note: The patient used HRT for 6 years, up to 55 years old.



(A) Vaginal mucosa in the basal condition with a thinner epithelium typical of atrophic vaginitis.

(B) The same patient one month after the second *MonaLisa Touch*® treatment session. It is evident the thicker epithelium of the mucosa.

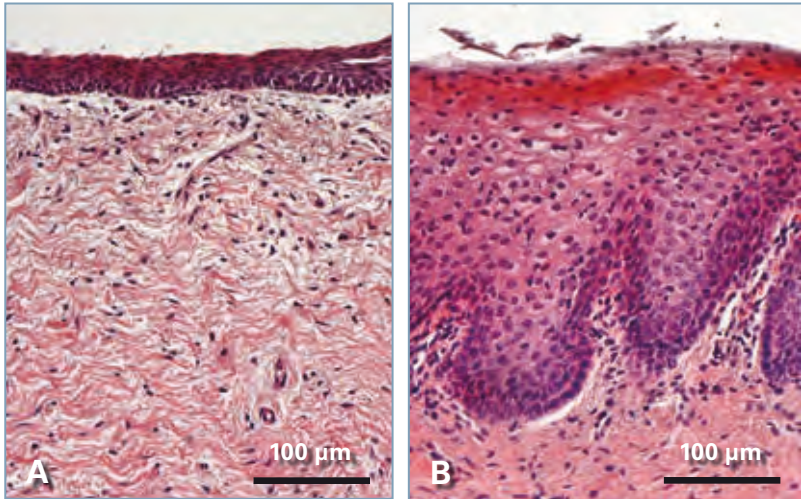
Pictures magnification 100x

Patient no.5:

Age: 54

Age at menopause: 53 years old

Note: The patient has never used HRT.



(A) Vaginal mucosa in the basal condition with a thinner epithelium typical of atrophic vaginitis.

(B) Vaginal mucosa of the same patient one month after the second *Monalisa Touch*® treatment session. The much thicker epithelium and shedding of numerous big cells from the free surface, together with the larger diameter of epithelial cells rich in glycogen, demonstrate the restored metabolic trophism and dynamics of the whole epithelium. Remark the connective tissue papillae projecting deeply into the underside of the epithelium.

APPENDIX B

***MonaLisa Touch*[®] Peer-Reviewed Scientific Publications**

A 12-week treatment with fractional CO₂ laser for vulvovaginal atrophy: a pilot study

S. Salvatore¹, R. E. Nappi², N. Zerbinati³, A. Calligaro⁴, S. Ferrero⁵, M. Origoni¹, M. Candiani¹, and U. Leone Roberti Maggiore¹

¹: Department of Obstetrics and Gynecology, Vita-Salute San Raffaele University and IRCCS San Raffaele Hospital, Milan, Italy. ²: IRCCS Policlinico S. Matteo Foundation and Department of Clinical, Surgical, Diagnostic and Pediatric Sciences, University of Pavia, Pavia, Italy. ³: University of Insubria, Varese, Italy. ⁴: University of Pavia, Pavia, Italy. ⁵: Department of Obstetrics and Gynecology, San Martino Hospital and National Institute for Cancer Research, University of Genoa, Genoa, Italy.

Corresponding author: U. Leone Roberti Maggiore, Department of Obstetrics and Gynaecology, IRCCS San Raffaele Hospital and Vita-Salute San Raffaele University, Via Olgettina 58-60, 20132 Milan, Italy; e-mail: ulrm@me.com.

Keywords: Fractional CO₂ laser, menopause, vaginal dryness, dyspareunia, vulvo-vaginal atrophy.

Abstract

Objective: This pilot study aimed to assess the efficacy and feasibility of fractional CO₂ laser in the treatment of vulvovaginal atrophy (VVA) in postmenopausal women.

Methods: VVA symptoms were assessed before and after three applications of laser over 12 weeks in 50 women (age 59.6 ± 5.8 years) dissatisfied with previous local estrogen therapies. Subjective (visual analog scale) and objective (Vaginal Health Index Score, VHIS) measures were used during the study period to assess VVA. Quality of life was measured by using the SF-12. A subjective scale to evaluate the degree of pain related to the laser application and the degree of difficulty to perform the laser procedure was used.

Results: Fractional CO₂ laser treatment was effective to improve VVA symptoms (vaginal dryness, vaginal burning, vaginal itching, dyspareunia, dysuria; $p < 0.001$) at 12-week follow-up, as well as the VHIS (13.1 ± 2.5 at baseline vs. 23.1 ± 1.9; $p < 0.001$). Both physical and mental scores of quality of life were significantly improved in comparison with baseline ($p < 0.001$). Satisfaction with the laser procedure was reported by 42 women (84%) and a minimal discomfort was experienced at the first laser application, mainly because of the insertion and the movements of the probe. Finally, the technique was very easy to perform in all women starting from the second application at week 4 and no adverse events were recorded during the study period.

Conclusions: A 12-week treatment with the fractional CO₂ laser was feasible and induced a significant improvement of VVA symptoms by ameliorating vaginal health in postmenopausal women. Further controlled studies should be performed to confirm the present data and to assess the long-term effects of the laser procedure on vaginal tissues.

Microablative fractional CO₂ laser improves dyspareunia related to vulvovaginal atrophy: a pilot study

S. Salvatore¹, U. Leone Roberti Maggiore¹, M. Origoni¹, M. Parma¹, L. Quaranta¹, F. Sileo¹, A. Cola¹, I. Baini¹, S. Ferrero², M. Candiani³, N. Zerbinati¹

¹: Obstetrics and Gynaecology Unit, Vita-Salute San Raffaele University and IRCCS San Raffaele Hospital, Milan – Italy. ²: Department of Obstetrics and Gynaecology, IRCCS San Martino Hospital and National Institute for Cancer Research, University of Genoa, Genoa – Italy. ³: Department of Surgical and Morphological Sciences, University of Insubria, Varese – Italy.

Corresponding author: U. Leone Roberti Maggiore, Department of Obstetrics and Gynaecology, IRCCS San Raffaele Hospital and Vita-Salute San Raffaele University, Via Olgettina 58-60, 20132 Milan, Italy; e-mail: ulrm@me.com.

Abstract

Objective: This pilot study aimed to assess the efficacy in treating sexually active menopausal patients who had dyspareunia related to vulvovaginal atrophy (VVA).

Materials and Methods: The intensity of VVA symptoms was recorded for each patient. Patients were administered the Short Form 12 (SF-12) and the female sexual function index (FSFI) to assess quality of life and sexual function, respectively. An objective evaluation of female urogenital health was performed using the Gloria Bachman Vaginal Health Index (VHI).

Results: At 12-week follow-up, the laser treatment was efficacious in improving dyspareunia in 100% of patients included in the study (n = 15). The intensity of dyspareunia significantly decreased from baseline (8.7 ± 1.0) to 12-week follow-up (2.2 ± 1.0 ; $p < 0.001$). In addition, all other VVA symptoms significantly ameliorated at the same follow-up. Furthermore, after the treatment, a significant improvement in quality of life (QoL) and sexual function were shown.

Conclusions: This pilot study demonstrated that treatment with the microablative fractional CO₂ laser of patients with dyspareunia related to VVA was efficacious at 12-week follow-up.

Microscopic and ultrastructural modifications of postmenopausal atrophic vaginal mucosa after fractional carbon dioxide laser treatment

N. Zerbinati¹, M. Serati², M. Origoni³, M. Candiani³, T. Iannitti⁴, S. Salvatore³, F. Marotta⁵, A. Calligaro⁶

¹: Department of Surgical and Morphological Sciences, University of Insubria, Varese, Italy. ²: Department of Obstetrics and Gynecology, University of Insubria, Varese, Italy. ³: Department of Gynecology, IRCCS San Raffaele Hospital, Milano, Italy. ⁴: School of Biomedical Sciences, University of Leeds, Leeds, UK. ⁵: ReGenera Research Group for Aging Intervention, Milan, Italy. ⁶: Department of Public Health, Experimental and Forensic Medicine, Histology and Embryology Unit, University of Pavia, Pavia, Italy

Corresponding author: T. Iannitti, School of Biomedical Sciences, University of Leeds, Mount Preston Street, Garstang building, Leeds LS2 9JT, UK; e-mail: tommaso.iannitti@gmail.com.

Keywords: Vaginal atrophy, regenerative medicine, fractional carbon dioxide laser.

Abstract

Vaginal atrophy occurring during menopause is closely related to the dramatic decrease in ovarian estrogens due to the loss of follicular activity. Particularly, significant changes occur in the structure of the vaginal mucosa, with consequent impairment of many physiological functions. In this study, carried out on bioptic vaginal mucosa samples from postmenopausal, nonestrogenized women, we present microscopic and ultrastructural modifications of vaginal mucosa following fractional carbon dioxide (CO₂) laser treatment. We observed the restoration of the vaginal thick squamous stratified epithelium with a significant storage of glycogen in the epithelial cells and a high degree of glycogen-rich shedding cells at the epithelial surface. Moreover, in the connective tissue constituting the lamina propria, active fibroblasts synthesized new components of the extracellular matrix including collagen and ground substance (extrafibrillar matrix) molecules. Differently from atrophic mucosa, newly-formed papillae of connective tissue indented in the epithelium and typical blood capillaries penetrating inside the papillae, were also observed. Our morphological findings support the effectiveness of fractional CO₂ laser application for the restoration of vaginal mucosa structure and related physiological trophism. These findings clearly coupled with striking clinical relief from symptoms suffered by the patients before treatment.

Sexual function after fractional microablative CO₂ laser in women with vulvovaginal atrophy.

S. Salvatore¹, R. E. Napp², M. Parma¹, R. Chionna¹, F. Lagona¹, N. Zerbinati³, S. Ferrero⁴, M. Origoni¹, M. Candiani¹, U. Leone Roberti Maggiore¹

¹: Department of Obstetrics and Gynecology, Vita-Salute San Raffaele University and IRCCS San Raffaele Hospital, Milan, Italy. ²: IRCCS Policlinico S. Matteo Foundation and Department of Clinical, Surgical, Diagnostic and Pediatric Sciences, University of Pavia, Pavia, Italy. ³: University of Insubria, Varese, Italy. ⁴: Department of Obstetrics and Gynecology, San Martino Hospital and National Institute for Cancer Research, University of Genoa, Genoa, Italy.

Corresponding author: U. Leone Roberti Maggiore, Department of Obstetrics and Gynaecology, IRCCS San Raffaele Hospital and Vita-Salute San Raffaele University, Via Olgettina 58-60, 20132 Milan, Italy; e-mail: ulrm@me.com.

Keywords: Fractional CO₂ laser, menopause, vaginal dryness, dyspareunia, sexual function, sexual intercourse, vulvovaginal atrophy.

Abstract

Objective: To investigate the effects of fractional microablative CO₂ laser on sexual function and overall satisfaction with sexual life in postmenopausal women with vulvovaginal atrophy (VVA).

Method: This prospective study included 77 postmenopausal women (mean age 60.6 ± 6.2 years) treated for VVA symptoms with the fractional microablative CO₂ laser system (SmartXide² V²LR, Monalisa Touch, DEKA, Florence, Italy). Sexual function and quality of life were evaluated with the Female Sexual Function Index (FSFI) and the Short Form 12 (SF-12), respectively, both at baseline and at 12-week follow-up. A 10-mm visual analog scale was used to measure the overall satisfaction with sexual life and the intensity of VVA symptoms (vaginal burning, vaginal itching, vaginal dryness, dyspareunia and dysuria) before and after the study period.

Results: We observed a significant improvement in the total score and the scores in each specific domain of the FSFI at 12-week follow-up compared to baseline ($p < 0.001$). After concluding the laser treatment, the overall satisfaction with sexual life significantly improved ($p < 0.001$). Seventeen (85%) out of 20 (26%) women, not sexually active because of VVA severity at baseline, regained a normal sexual life at the 12-week follow-up. Finally, we also found a significant improvement in each VVA symptom ($p < 0.001$) and in quality-of-life evaluation, both for the scores in the physical ($p = 0.013$) and mental ($p = 0.002$) domains.

Conclusions: Fractional microablative CO₂ laser treatment is associated with a significant improvement of sexual function and satisfaction with sexual life in postmenopausal women with VVA symptoms.

Vulvo-vaginal atrophy: A new treatment modality using thermo-ablative fractional CO₂ laser

A. Perino¹, A. Calligaro², F. Forlani³, C. Tiberio¹, G. Cucinella¹, A. Svelato¹, S. Saitta⁴, G. Calagna¹

¹: Department of Obstetrics and Gynaecology, University Hospital "P. Giaccone", Palermo, Italy. ²: Department of Public Health, Experimental and Forensic Medicine, Unit of Histology and Embryology University of Pavia, Pavia, Italy. ³: Department of Obstetrics and Gynaecology, University Hospital "P. Giaccone", Palermo, Italy. ⁴: Department of Human Pathology, School and Division of Allergy and Clinical Immunology, University of Messina, Messina, Italy.

Corresponding author: F. Forlani, Department of Obstetrics and Gynaecology, University Hospital "P. Giaccone", Palermo, Italy; e-mail: forlani81@gmail.com.

Keywords: Laser treatment, menopause, vulvo-vaginal atrophy.

Abstract

Objective: To evaluate the efficacy and feasibility of thermo-ablative fractional CO₂ laser for the treatment of symptoms related to vulvo-vaginal atrophy (VVA) in post-menopausal women.

Method: From April 2013 to December 2013, post-menopausal patients who complained of one or more VVA-related symptoms and who underwent vaginal treatment with fractional CO₂ laser were enrolled in the study. At baseline (T0) and 30 days post-treatment (T1), vaginal status of the women was evaluated using the Vaginal Health Index (VHI), and subjective intensity of VVA symptoms was evaluated using a visual analog scale (VAS). At T1, treatment satisfaction was evaluated using a 5-point Likert scale.

Results: During the study period, a total of 48 patients were enrolled. Data indicated a significant improvement in VVA symptoms (vaginal dryness, burning, itching and dyspareunia) ($P < 0.0001$) in patients who had undergone 3 sessions of vaginal fractional CO₂ laser treatment. Moreover, VHI scores were significantly higher at T1 ($P < 0.0001$). Overall, 91.7% of patients were satisfied or very satisfied with the procedure and experienced considerable improvement in quality of life (QoL). No adverse events due to fractional CO₂ laser treatment occurred.

Conclusions: Thermo-ablative fractional CO₂ laser could be a safe, effective and feasible option for the treatment of VVA symptoms in post-menopausal women.

Histological study on the effects of microablative fractional CO₂ laser on atrophic vaginal tissue: an ex vivo study

S. Salvatore¹, U. Leone Roberti Maggiore¹, S. Athanasiou², M. Origoni¹, M. Candiani¹, A. Calligaro³, N. Zerbinati⁴

¹: Obstetrics and Gynecology Unit, Vita-Salute San Raffaele University and IRCCS San Raffaele Hospital, Milan, Italy. ²: Urogynecology Unit, First Department of Obstetrics and Gynecology, National and Kapodistrian University of Athens, Athens, Greece. ³: Department of Experimental Medicine, Histology, and Embryology, University of Pavia, Pavia, Italy. ⁴: Department of Dermatology, University of Insubria, Varese, Italy.

Corresponding author: U. Leone Roberti Maggiore, Department of Obstetrics and Gynaecology, IRCCS San Raffaele Hospital and Vita-Salute San Raffaele University, Via Olgettina 58-60, 20132 Milan, Italy; e-mail: ulrm@me.com.

Keywords: Aging, microablative fractional CO₂ laser, menopause, pelvic organ prolapse, vulvovaginal atrophy.

Abstract

Objective: Microablative fractional CO₂ laser has been proven to determine tissue remodeling with neof ormation of collagen and elastic fibers on atrophic skin. The aim of our study is to evaluate the effects of microablative fractional CO₂ laser on postmenopausal women with vulvovaginal atrophy using an ex vivo model.

Method: This is a prospective ex vivo cohort trial. Consecutive postmenopausal women with vulvovaginal atrophy managed with pelvic organ prolapse surgical operation were enrolled. After fascial plication, the redundant vaginal edge on one side was treated with CO₂ laser (SmartXide²; DEKA Laser, Florence, Italy). Five different CO₂ laser setup protocols were tested. The contralateral part of the vaginal wall was always used as control. Excessive vagina was trimmed and sent for histological evaluation to compare treated and nontreated tissues. Microscopic and ultrastructural aspects of the collagenic and elastic components of the matrix were studied, and a specific image analysis with computerized morphometry was performed. We also considered the fine cytological aspects of connective tissue proper cells, particularly fibroblasts.

Results: During the study period, five women were enrolled, and 10 vaginal specimens were finally retrieved. Four different settings of CO₂ laser were compared. Protocols were tested twice each to confirm histological findings. Treatment protocols were compared according to histological findings, particularly in maximal depth and connective changes achieved. All procedures were uneventful for participants.

Conclusions: This study shows that microablative fractional CO₂ laser can produce a remodeling of vaginal connective tissue without causing damage to surrounding tissue.

The use of pulsed CO₂ lasers for the treatment of vulvovaginal atrophy.

S. Salvatore¹, S. Athanasiou², M. Candiani¹

¹:Obstetrics and Gynecology Unit, Vita-Salute San Raffaele University, IRCCS San Raffaele Hospital, Milan, Italy. ²: Urogynecology Unit, First Department of Obstetrics and Gynecology, National & Kapodistrian University of Athens, Athens, Greece.

Corresponding author: Salvatore Stefano, Department of Obstetrics and Gynecology, San Raffaele Hospital, Via Olgettina 60, 20132, Milan, Italy. Tel: +39 02 26432653;p39 347 2757131; fax: +39 02 26432759; e-mail: salvatore.stefano@hsr.it.

Keywords: dyspareunia, pulsed CO₂ laser, quality of life, sexual function, vaginal dryness, vulvovaginal atrophy.

Abstract

Purpose of Review: This article reviews the literature regarding the safety and efficacy of the use of a pulsed CO₂ laser for the treatment of vulvovaginal atrophy (VVA).

Recent Findings: Prospective observational studies have demonstrated histological changes after the use of pulsed CO₂ laser vaginally in atrophic conditions. Increased collagen and extracellular matrix production has been reported together with an increase in the thickness of the vaginal epithelium with the formation of new papilla. Three different observational studies reported a significant improvement of VVA assessed subjectively (with a 10-point visual analogue scale) and objectively (using the Vaginal Health Index) after a cycle of three treatments of pulsed CO₂ laser. Also sexual function (assessed with the Female Sexual Function Index) and quality of life (evaluated with the SF12 questionnaire) significantly improved. No complications or side-effects were reported during or after the laser procedure that was performed in an outpatient setting.

Summary: Increasing evidence with histological and clinical data supports the use of pulsed CO₂ lasers in the treatment of VVA; however, no randomized control trial (sham versus treatment) has yet been produced and no data on the duration of therapy are currently available.

Fractional CO₂ laser for vulvovaginal atrophy (VVA) dyspareunia relief in breast cancer survivors

A. Pieralli^{1,2}, M.G. Fallani¹, A. Becorpi¹, C. Bianchi¹, S. Corioni¹, M. Longinotti¹, Z. Tredici¹, S. Guaschino¹

¹: Section of Gynecology and Obstetrics, Department of Woman and Child Health, Careggi University Hospital, Largo Brambilla 3, 50144, Florence, Italy. ²: Largo Brambilla 3, 50134, Florence, Italy.

Corresponding author: Annalisa Pieralli clbianchi85@gmail.com.

Keywords: Vulvovaginal atrophy, laser, oncological menopause, breast cancer survivors.

Abstract

Purpose: The aim of this study was to evaluate the efficacy of fractional CO₂ laser therapy in breast cancer survivors as a therapeutic method for vulvovaginal atrophy (VVA) dyspareunia.

Methods: 50 patients (mean age 53.3 years) underwent fractional microablative CO₂ laser treatment for dyspareunia in oncological menopause (mean time of menopause 6.6 years). The Gloria Bachmann's Vaginal Health Index (VHI) score was chosen as system to evaluate the presence of VVA and its improvement after the treatment. Intensity of dyspareunia was evaluated using a visual analog scale (VAS).

Results: Data indicated a significant improvement in VVA dyspareunia ($p < 1.86 \times 10^{-22}$) in breast cancer survivors who had undergone 3 sessions of vaginal fractional CO₂ laser treatment. Moreover, VHI scores were significantly higher 30 days post-treatment (T4) ($p < 0.0001$). 76 % of patients were satisfied or very satisfied with the treatment results. The majority (52 %) of patients were satisfied after a long-term follow-up (mean time 11 months). No adverse events due to fractional CO₂ laser treatment occurred.

Conclusions: The treatment with fractionated CO₂ laser appeared to be a feasible and effective treatment for VVA dyspareunia in breast cancer survivors with contraindications to hormonal treatments.

Is vaginal fractional CO₂ laser treatment effective in improving overactive bladder symptoms in post-menopausal patients? Preliminary results

A. Perino¹, G. Cucinella², G. Gugliotta³, S. Saitta⁴, S. Polito⁵, B. Adile², R. Marc⁵, G. Calagna¹.

¹:Department of Obstetrics and Gynaecology, University Hospital, Palermo, Italy; ²: Urogynecology Unit, 'Villa Sofia-Cervello' Hospital, Palermo, Italy; ³: Department of Human Pathology, School and Division of Allergy and Clinical Immunology, University of Messina, Messina, Italy; ⁴: Department of Obstetrics and Gynaecology, "Barone I. Romeo" Hospital, Patti (Messina), Italy; ⁵: Department of Morphology Surgery and Experimental Medicine, University of Ferrara, Ferrara, Italy.

Corresponding author: Gloria Calagna, MD; e-mail: gloria.calagna83@gmail.com.

Keywords: CO₂ laser, overactive bladder, menopause, vul-vo-vaginal atrophy.

Abstract

Objective: To evaluate the role of vaginal fractional CO₂ laser treatment in the relief of Overactive Bladder (OAB) symptoms in post-menopausal women.

Patients and Methods: Post-menopausal women who complained of one or more symptoms related to vulvo-vaginal atrophy (VVA), who experienced symptoms of OAB and who underwent vaginal treatment with fractional CO₂ laser were enrolled in the study. At baseline (T0) and 30 days post-treatment (T1), vaginal status (using Vaginal Health Index - VHI), subjective intensity of VVA symptoms (using a visual analog scale - VAS) and micturition diary were evaluated. OAB symptoms were also assessed using a validated questionnaire.

Results: Thirty patients were enrolled. A statistically significant improvement in VVA symptoms was observed and in VHI at T1 ($p < 0.0001$). A significant improvement was also identified in the micturition diary, in number of urge episodes and OAB-q ($p < 0.0001$). Nine of the 30 patients suffered from incontinence episodes and had improved at T1.

Conclusions: We showed that fractionated CO₂ laser vaginal treatment has proved to be effective in improving OAB symptoms in post-menopausal women. Moreover, it is a safe and efficacious measure for the relief of VVA related conditions. Further long-term studies are needed to confirm these preliminary results.

The effect of microablative fractional CO₂ laser on vaginal flora of postmenopausal women

S. Athanasiou¹, E. Pitsouni^{1,2}, S. Antonopoulou³, D. Zacharakis¹, S. Salvatore⁴, M.E. Falagas^{2,5,6}, T. Grigoriadis¹.

¹: Urogynecology Unit, 1st Department of Obstetrics and Gynecology, "Alexandra" Hospital, Medical School, National and Kapodistrian University of Athens, Athens, Greece; ²: Alpha Institute of Biomedical Sciences (AIBS), Athens, Greece; ³: Microbiology Department, "G. Gennimatas" General Hospital, Athens, Greece; ⁴: Obstetrics and Gynecology Unit, Vita-Salute San Raffaele University, IRCCS San Raffaele Hospital, Milan, Italy Urogynecology Unit; ⁵: Department of Medicine-Infectious Diseases, IASO General Hospital, Athens, Greece; ⁶: Department of Medicine, Tufts University School of Medicine, Boston, MA, USA.

Corresponding author: Assistant Professor S. Athanasiou stavros.athanasiou@gmail.com Urogynecology Unit, 1st Department of Obstetrics and Gynecology, "Alexandra" Hospital, Medical School, National and Kapodistrian University of Athens, Vasilisis Sofias Ave. 80, 11528, Athens, Greece.

Keywords: Vaginal atrophy; menopause; intravaginal therapy; urinary tract infections; UTIs; vaginitis; urogenital infections; dyspareunia.

Abstract

Objective: To assess the effect of microablative fractional CO₂ laser (MFCO₂-Laser) therapy on the vaginal microenvironment of postmenopausal women.

Methods: Three laser therapies at monthly intervals were applied in postmenopausal women with moderate to severe symptoms of genitourinary syndrome of menopause, pH of vaginal fluid >4.5 and superficial epithelial cells on vaginal smear <5%. Vaginal fluid pH values, fresh wet mount microscopy, Gram stain and aerobic and anaerobic cultures were evaluated at baseline and 1 month after each subsequent therapy. Nugent score and Hay-Ison criteria were used to evaluate vaginal flora.

Results: Fifty-three women (mean age 57.2±5.4 years) participated and completed this study. MFCO₂-Laser therapy increased Lactobacillus (p<0.001) and normal flora (p<0.001) after the completion of the therapeutic protocol, which decreased vaginal pH from a mean of 5.5±0.8 (initial value) to 4.7±0.5 (p<0.001). The prevalence of Lactobacillus changed from 30% initially to 79% after the last treatment. Clinical signs and symptoms of bacterial vaginosis, aerobic vaginitis or candidiasis did not appear in any participant.

Conclusions: MFCO₂-Laser therapy is a promising treatment for improving the vaginal health of postmenopausal women by helping repopulate the vagina with normally existing Lactobacillus species and reconstituting the normal flora to premenopausal status.

An assessment of the safety and efficacy of a fractional CO₂ laser system for the treatment of vulvovaginal atrophy

E.R. Sokol¹, M.M. Karram².

¹:Division of Urogynecology and Pelvic Reconstructive Surgery, Stanford University, Stanford, CA;

²: Advanced Urogynecology and Pelvic Surgery, The Christ Hospital, Cincinnati, OH.

Corresponding author: Eric R. Sokol, MD, Stanford University School of Medicine, 300 Pasteur Drive, Room G332, Stanford, CA 94305. E-mail: esokol@stanford.edu.

Keywords: Dyspareunia; fractional CO₂ laser; genitourinary syndrome of menopause; menopause; vaginal dryness; vulvovaginal atrophy.

Abstract

Objective: The aim of the study was to assess the safety and efficacy of a novel fractional CO₂ laser for the treatment of genitourinary syndrome of menopause (GSM).

Methods: Women presenting with GSM and meeting study criteria were enrolled. Examinations at baseline and follow-up (3 mo after final treatment) evaluated dilator tolerance and vaginal pH. Visual analog scales were used to assess pain, vaginal burning, vaginal itching, vaginal dryness, dyspareunia, and dysuria; Vaginal Health Index scores were completed before each treatment and at follow-up; Female Sexual Function Index and Short Form 12 questionnaires were also completed. Participant satisfaction was measured on a 5-point Likert scale (1=very dissatisfied, 5=very satisfied). Women received three laser treatments, 6 weeks apart.

Results: Thirty women participated (mean age 58.6±8.8 y). None withdrew or were discontinued due to an adverse event; three were lost to follow-up. Average improvement in visual analog scale scoring was 1.7±3.2 for pain, 1.4±2.9 for burning, 1.4±1.9 for itching, 6.1±2.7 for dryness, 5.1±3.0 for dyspareunia, and 1.0±2.4 for dysuria; improvement in average Vaginal Health Index and Female Sexual Function Index scores were statistically significant ($P<0.001$). Twenty-five of 30 participants (83%) showed increase in comfortable dilator size at 3-month follow up. Before the second and third treatments, 86.6% (26 of 30) of women reported they were better or much better than at the previous treatment; 26 of 27 women (96%) were reportedly satisfied or extremely satisfied at follow-up.

Conclusions: In this sample, the data suggest that the fractional CO₂ laser is effective and safe for treatment of the symptoms associated with GSM.

Fractional microablative CO₂ laser for vulvovaginal atrophy in women treated with chemotherapy and/or hormonal therapy for breast cancer: a retrospective study

T. Pagano¹, P. De Rosa¹, R. Vallone¹, F. Schettini², G. Arpino², S. De Placido, G. Nazzaro¹, M. Locci¹, G. De Placido¹.

¹: Reproductive Medicine Unit, Department of Neuroscience, Reproductive Medicine, Odontostomatology.

²: Medical Oncology, Department of Clinical and Surgical Medicine, University of Naples "Federico II", Naples, Italy.

Corresponding author: Francesco Schettini, MD, Medical Oncology, Department of Clinical and Surgical Medicine, University of Naples "Federico II", Via Sergio Pansini 5, Naples 80131, Italy. E-mail: francescoschettini1987@gmail.com.

Keywords: Breast cancer; CO₂ laser therapy; wstrogen preparations; hormone receptors; vulvovaginal atrophy.

Abstract

Objective: Breast cancer is one of the most common malignancies in women. Hormonal treatment and chemotherapy induce a transient or permanent menopause status. Vulvovaginal atrophy (VVA) is a frequent debilitating symptom of menopause that is best treated with local or systemic estrogen formulations. Because estrogens drive the growth of the majority of breast cancers, most effective VVA therapies are precluded. The aim of this study was to evaluate the effects of fractional microablative CO₂ laser on sexual function and in relieving symptoms in women with breast cancer and VVA induced or exacerbated by iatrogenic menopause.

Methods: This retrospective study included 26 women affected by hormone-receptor positive breast tumors and treated for VVA symptoms with the fractional microablative CO₂ laser system. Every 30 to 40 days, women underwent a cycle of treatment for a total of three cycles. During each cycle, women underwent a gynecological examination and completed visual analog scale questionnaires designed to assess (1) the degree of symptoms and (2) procedure-related discomfort.

Results: Treatment resulted in a significant regression of VVA symptoms and procedure-related discomfort versus baseline ($P < 0.001$ in almost all cases). No adverse reactions were observed nor reported by women.

Conclusions: Fractional microablative CO₂ laser treatment is associated with a significant improvement of VVA symptoms in women affected by hormone-driven breast cancer. This procedure has the advantage of relieving iatrogenic/physiological VVA symptoms without resorting to contraindicated estrogen preparations, which have been the most effective therapy thus far.

The curative effect and feasibility analysis of fractional CO₂ laser in the treatment of vulvovaginal in postmenopausal women

Y. Miao, J. Li, J. Wang

Department of Obstetrics and Gynecology, Peking University People's Hospital, Beijing 100044, China.

Corresponding author: Jianliu Wang - Department of Obstetrics and Gynecology, Peking University People's Hospital, Beijing 100044, China. E-mail: wangjianliu@pkuph.edu.cn.

Keywords: Fractional CO₂ laser; postmenopause; vulvovaginal atrophy; curative effect; feasibility.

Abstract

Objectives: This prospective study aimed to assess the curative efficacy and feasibility of fractional CO₂ laser in the treatment of vulvo-vaginal atrophy (VVA) in postmenopausal women.

Methods: 30 patients with VVA recruited in this study, fractional CO₂ laser treatment was applied, visual analogue scale (VAS) and vaginal health index score (VHIS) measures were used to assess VVA, and degree of pain before and after the treatment, additionally, satisfaction survey was done post treatment.

Results: Fractional CO₂ laser treatment was significant improved VVA symptoms (vaginal itching, 6.00±2.60 vs. 1.38±0.97, P<0.001; vaginal dryness 7.04±2.26 vs. 1.88±1.03, P<0.001; vaginal burning, 6.25±2.13 vs. 1.50±0.88, P<0.001; dyspareunia, 7.54±2.54 vs. 2.04±1.15, P<0.001), as well as the VHIS (9.79±2.76 vs. 16.33±2.06, P<0.001). Satisfaction with the laser procedure was reported by 28 women (93.33%) and a minimal discomfort was experienced at the laser application. No adverse events were recorded.

Conclusions: The fractional CO₂ laser treatment can improve the VVA symptoms in postmenopausal patients with vulvo-vaginal atrophy and was proved to be a simple, outpatient therapy for VVA patients.

The application of fractional CO₂ laser in the treatment of vulvar lichen sclerosis

J. Li, Y. Miao, J. Wang

Department of Obstetrics and Gynecology, Peking University People's Hospital, Beijing 100044, China.

Corresponding author: Jianliu Wang - Department of Obstetrics and Gynecology, Peking University People's Hospital, Beijing 100044, China. E-mail: wangjianliu@pkuph.edu.cn.

Keywords: Fractional carbon dioxide laser; vulvar lichen sclerosis; pruritus; effect.

Abstract

Objectives: To investigate the efficacy and side effects for fractional CO₂ laser in the treatment of vulvar lichen sclerosis (VLS).

Methods: 31 patients with VLS symptoms were enrolled prospectively from July 2015 to April 2016 in Peking University People's Hospital. The fractional CO₂ laser was used for VLS lesions, a total of 3-5 times, each time per-month. Visual analogue scale (VAS) was assessed the degree of vulvar pruritus, skin chapping, dyspareunia before and after treatment. After the treatment, satisfaction survey was done.

Results: The rate improvement of VLS symptoms was 90.32% (28/31) with fractional CO₂ laser ($P<0.001$). Compare with before treatment, there were significant difference in pruritus score at the first and the third after treatment one month (8.07 ± 1.97 vs. 3.43 ± 0.94 and 1.93 ± 0.62 , $P<0.001$), vulvar skin chapping score (3.5 ± 1.79 vs. 1.36 ± 1.22 and 0.64 ± 0.84 , $P<0.005$), respectively. The dyspareunia score (4.29 ± 2.70 vs. 1.14 ± 0.95 , $P<0.05$) were improved significantly at the third after treatment one month. After treatment 48h, there were 2 cases with mild pain, 6 cases with local mils hyperemia, 4 cases with mild swelling. No adverse events due to fractional CO₂ laser treatment occurred. During 3-7 months follow-up, 4 cases (12.9%) with the skin color from white to gray, 2 cases recovered sex from 6 cases. The overall satisfaction rate was 96.77% (30/31).

Conclusions: The fractional CO₂ laser is effective, minimal injury and acceptable side effects for vulvar lichen sclerosis, and may be a new treatment for it.

Microablative fractional CO₂-laser therapy and the genitourinary syndrome of menopause: An observational study

E. Pitsouni¹, T. Grigoriadis¹, A. Tsiveleka², D. Zacharakis¹, S. Salvatore³, S. Athanasiou¹

¹: Urogynecology Unit, 1st Department of Obstetrics and Gynecology, "Alexandra" Hospital, Medical School, National and Kapodistrian University of Athens, Athens – Greece. ²: Cytology Department, "Alexandra Hospital", Athens - Greece. ³: Obstetrics and Gynecology Unit, Vita-Salute San Raffaele University, IRCCS San Raffaele Hospital, Urogynecology Unit, Milan - Italy.

Corresponding author: Stavros Athanasiou. E-mail addresses: athanasio@otenet.gr, stavros.athanasiou@gmail.com.

Keywords: Menopause; urinary incontinence; urgency; sexual function; dyspareunia; vulvovaginal atrophy.

Abstract

Objectives: This study aimed to assess the effect of the Microablative Fractional CO₂ Laser (CO₂-laser) therapy on vaginal pathophysiology and the symptoms of the Genitourinary Syndrome of Menopause (GSM).

Methods: Postmenopausal women with moderate to severe symptoms of GSM underwent three sessions of CO₂-laser therapy at monthly intervals. Participants were evaluated at baseline and 4 weeks after the last treatment.

Main Outcome Measures: The primary outcomes were Vaginal Maturation Value (VMV) and Vaginal Health Index Score (VHIS). Secondary outcomes included symptoms of GSM, Female Sexual Function Index (FSFI), International Consultation on Incontinence Questionnaire of Female Urinary Tract Symptoms (ICIQ-FLUTS) and Urinary Incontinence Short Form (ICIQ-UI SF), Urogenital Distress Inventory (UDI-6) and King's Health Questionnaire (KHQ).

Results: Fifty-three postmenopausal women completed this study. VMV, VHIS and FSFI increased significantly. Dyspareunia, dryness, burning, itching, dysuria, frequency, urgency, urgency incontinence, stress incontinence and scores on the ICIQ-FLUTS, ICIQ-UI SF, UDI-6 and KHQ decreased significantly. Factors predicting for which women the CO₂-laser therapy was more effective were not identified.

Conclusions: This study suggests that intravaginal CO₂-laser therapy for postmenopausal women with clinical signs and symptoms of GSM may be effective in improving both vaginal pathophysiology and reported symptoms.

Fractional CO₂ laser treatment of the vestibule for patients with vestibulodynia and genitourinary syndrome of menopause: a pilot study

F. Murina¹, M. Karram², S. Salvatore³, R. Felice¹.

¹: Lower Genital Tract Disease Unit, V. Buzzi Hospital, University of Milan, Milan, Italy. ²: Division of Female Pelvic Medicine and Reconstructive Surgery, The Christ Hospital Department of Obstetrics and Gynecology, Cincinnati, OH, USA. ³: Department of Obstetrics and Gynecology, Vita-Salute San Raffaele University and IRCCS San Raffaele Hospital, Milan, Italy.

Corresponding author: Mickey Karram. Electronic address: Mickey.Karram@thechristhospital.com. Division of Female Pelvic Medicine and Reconstructive Surgery, The Christ Hospital Department of Obstetrics and Gynecology, Cincinnati, OH, USA.

Keywords: Fractional CO₂ laser; genitourinary syndrome of menopause; vestibulodynia.

Abstract

Introduction: Chronic vulvar pain and burning remains one of the most perplexing problems faced by practicing gynecologists.

Aim: To evaluate the effectiveness and safety of the application of micro-ablative fractional CO₂ laser to the vulvar vestibule in the management of patients with vulvar pain from vestibulodynia or genitourinary syndrome of menopause.

Methods: Patients (N = 70) underwent fractional micro-ablative CO₂ laser treatment for vestibular pain plus vestibulodynia (n = 37) or genitourinary syndrome of menopause (n = 33). Inclusion criteria were the existence of vestibular atrophic changes and the absence of moderate or severe pelvic floor hypertonic dysfunction.

Main Outcome Measures: A visual analog scale of pain and the Marjoff score of dyspareunia were chosen to evaluate improvement. Grading of vestibular health also was quantified using a four-point scoring system (0 = no atrophy, 3 = severe atrophy). Data were collected at baseline, at weeks 4, 8, and 12, and 4 months after the final treatment.

Results: For visual analog scale and dyspareunia scoring and for the overall vestibular health index scoring, statistically significant improvement was noted after three sessions of vestibular fractional CO₂ laser treatment. Improvement gradually increased throughout the study period and was maintained through the 4-month follow-up visit. There was no statistically significant difference in outcomes between the two study groups. No adverse events from fractional CO₂ laser treatment were noted. Overall, 67.6% of patients stated significant improvement from the laser procedure.

Conclusion: This preliminary case series showed encouraging results using fractional CO₂ laser treatment of the vestibule in women with vestibulodynia and genitourinary syndrome of menopause.

Fractional CO₂ laser treatment for vaginal atrophy and vulvar lichen sclerosis

M.S. Baggish¹.

¹: St. Helena Hospital, St. Helena, CA, and Department of Obstetrics and Gynecology, University of California - San Francisco, CA - USA.

Corresponding author: Michael S. Baggish, MD. 1576 Voorhees Circle St. Helena, CA 94574.
E-mail: mbaggish@gmail.com.

Keywords: Fractional CO₂ laser, vaginal atrophy, lichen sclerosis.

Abstract

Objectives: The aim of this research was to assess the efficacy of fractional CO₂ laser energy for treating vaginal atrophy and lichen sclerosis.

Materials and Methods: The first study population was 23 postmenopausal women diagnosed with vaginal atrophy via microscopic evaluation and who were symptomatic. The second study population was 27 postmenopausal women diagnosed with lichen sclerosis by biopsy and who were symptomatic. Patients with vaginal atrophy had 3 treatment sessions spaced at 4–6 weeks between each session. Laser settings for this group were: power: Watts, 30; time, 1000 microseconds; and spacing, 1000 micrometers. For the lichen sclerosis group, the power was set at 20 Watts and 3–4 treatments were given at 4–6-week intervals.

Results: In the vaginal atrophy cohort, 22/23 women who previously complained of dryness and discomfort had these symptoms alleviated and vaginal microscopic exam showed significant changes in color, elasticity, and wetness following 3 courses of CO₂ laser fractional treatment; additionally 20/23 women had elimination of urinary frequency and urgency, 18/21 women had alleviation of dyspareunia. In the lichen sclerosis cohort 24/27 patients who had laser treatment reported cessation of itching and pain/discomfort; and 26/27 women demonstrated visible improvement of skin color, elasticity, vascularity following 3-4 laser treatments. All examinations were performed with the operating microscope.

Conclusions: The fractional CO₂ laser beam is useful for treating vaginal atrophy and lichen sclerosis. This new technique represents a significant divergence from estrogenic-, steroid- and corticosteroid-bulwark dependence. All treatments were performed in an office setting and were associated with either no pain or, at the most, minimal and temporary discomfort. This new use of the CO₂ laser is an excellent alternative for managing these two troublesome problems, particularly in postmenopausal women.

Fractional CO₂ laser treatment: a novel approach for stress urinary incontinence management in post-menopausal women

P. González Isazaa^{1,2}, A. I. Ruiz Rosas^{3,4,5,6}, D. L. Vélez Rizo⁷

¹: Ginecología y Obstetricia, Universidad Militar de Colombia, Bogotá, Colombia. ²: Uroginecología y Piso pélvico, Cirugía Láser y Reconstructiva ginecológica, Presidente de la Asociación de Ginecólogos Estéticos Colombianos (AGEOC), Miembro Asociación Internacional Uroginecológica (IUGA), Pereira, Risaralda, Colombia. ³: Medicina Estética Magister, Universitat Les IllesBalears, España. ⁴: Docente de Dermatología, Universidad Nacional de Colombia, Bogotá, Colombia. ⁵: Directora de Laser Medical Care, Bogotá, Colombia. ⁶: Miembro ASMLS Bogotá DC, Cundinamarca, Colombia. ⁷: Ginecología y Obstetricia, Universidad de la Sabana, Bogotá, Colombia.

Corresponding author: Pablo González Isazaa. E-mail address: pagonza@hotmail.com. Urogynecological private office, Megacentro Pinares, Pereira, Colombia.

Keywords: Vaginal atrophy, menopause, laser CO₂, quality of life, urinary incontinence, vulvovaginal.

Abstract

Objectives: To describe the results of the fractional CO₂ laser as an alternative treatment for stress urinary incontinence in post-menopausal women, and to demonstrate an improvement in quality of life after the treatment.

Materials and Methods: A prospective, single centre descriptive study was conducted on 10 post-menopausal patients with diagnosis of stress urinary incontinence. Recruited patients were evaluated with Stress Cough test and urethral Mobility Q-Tip Test, which confirmed the diagnosis. They then began a 3 session treatment protocol; 1 every 3 weeks using the SmartXide² V²LR fractional microablative CO₂ laser system for the MonaLisa TouchTM procedure in the urethrovaginal junction. The Urogenital Distress Inventory UDI-6 was performed to evaluate severity and quality of life impact related to stress urinary incontinence in the patients included in the study, before and after treatment. Patients were monitored from July to December 2013.

Results: Analysis of the UDI-6 Scores before and at the end of treatment showed an improvement in the score in comparison to the baseline condition, indicating a subjective improvement in all the symptoms related to SUI included in the score.

Conclusions: The MonaLisa TouchTM procedure performed with SmartXide² V²LR laser system is a complementary alternative to traditional surgical techniques, providing a safe and effective treatment for urinary incontinence in post-menopausal women.

APPENDIX C

MonaLisa Touch[®] White Papers

Menopausal Vaginal Atrophy Treatment with Microablative Fractional CO₂ Laser. A New Approach.

Pablo González Isaza¹, Aura Ibeth Ruiz Rosas², Luisa Galindo³.

¹: Specialist in Gynecology and Obstetrics. Expert in Laser Surgery and Reconstructive Surgery of the pelvic floor. Head of Urogynecology Unit, University Hospital Pereira Colombia. Member of the International Urogynecological Association (IUGA). ²: Teacher in Aesthetics Medicine, University of Les Illes Balears, Spain. Professor in Dermatology at the National University of Colombia, Bogotá. Scientific Director of Medical Care Clinic, Bogotá, Colombia. ³: Third year resident in Dermatology, Faculty of Medicine, National University of Colombia, Bogotá.

English translation of:

Pablo González Isaza, Aura Ibeth Ruiz Rosas, Luisa Galindo. Tratamiento de la atrofia vaginal en la menopausia con microablacion con laser de CO₂ fraccionado. Un nuevo enfoque. Revista de Enfermedades del Tracto Genital Inferior. COMEGIC. 2014, 8(1); pp. 36-40.

Abstract

Vulvo-vaginal atrophy is a public health problem¹ involving 50% of women in menopause who may have a variety of related symptoms. These are due to the natural physiological ageing process² that also involves the vaginal mucosa. The loss of reticular configuration by the extracellular matrix of the connective tissue causes incorrect hydration of mucosa and problems with the vaginal trophism. Until now available treatments have shown partial effectiveness. By applying the principles of regenerative and anti-aging medicine the use of a CO₂ laser system, with pulsed emission specifically created for vaginal mucosa treatment, induces important molecular events in the connective tissue matrix restoring the correct vaginal trophism. Treated patients referred significant clinical benefits also associated with an improvement in the sexual function and the quality of life. The Vaginal Health Index of Gloria Bachman (table 1) was applied to 55 voluntary patients ranging from 37 to 63 years old (average age: 52). Patients began a treatment protocol using the SmartXide² V²LR - *MonaLisa Touch*[®] fractional microablative CO₂ laser system showed a significant score change in comparison to the baseline conditions. Moreover, all patients indicated subjective improvement in all the symptoms of vaginal atrophy.

Keywords: vaginal atrophy, menopause, laser, quality of life, sexual function.



Use of the *MonaLisa Touch*® Treatment on Cancer Patients

Maurizio Filippini, M.D. - Miriam Farinelli, M.D.

Gynaecological Endoscopy Functional Unit of the Republic of San Marino State Hospital.

Abstract

Objective: This pilot study aimed to assess the efficacy in treating atrophic vaginitis symptoms in those women who cannot receive local or systemic hormone-based therapies, since they have had a hormone-sensitive tumour.

Methods: 46 treatments with the *MonaLisa Touch*® were performed from 01/23/2013 to 10/31/2014 at the Republic of San Marino State Hospital involved patients with neoplasias. The intensity of atrophic vaginitis symptoms was recorded for each patient.

Results: About two months after the first treatment the percent reduction of the individual symptoms was very significant, not unlike that obtained from patients who received the treatment but without neoplastic pathologies. Furthermore, after the treatment, a significant improvement in quality of life was shown.

Conclusions: Considering the absence of complications and especially the absence of contraindications, the *MonaLisa Touch*® laser treatment is a valuable and irreplaceable aid for all patients who cannot and prefer not to receive hormone replacement therapy.

Keywords: Vaginal atrophy, oestrogen-sensitive tumour, induced menopause, laser.



Use of the *MonaLisa Touch*[®] Treatment for Post-Partum Dyspareunia. A Pilot Study

Maurizio Filippini, M.D. - Miriam Farinelli, M.D.

Gynaecological Endoscopy Functional Unit of the Republic of San Marino State Hospital.

Abstract

Objective: This pilot study aimed to assess the efficacy in treating perineal pain symptoms in women who had late post-partum dyspareunia.

Methods: The study involved six patients who had late post-partum dyspareunia. Over a time period from January 1, 2013 through August 31, 2014, patients were subjected to *MonaLisa Touch*[®] CO₂ laser treatment.

Results: Study results showed that two months after the treatment, out of a total of six patients, four treated for pain following episiorrhaphy or vaginal tear reported improvement in symptoms. The other two patients who underwent cesarian section, one has noticed a significative improvement while the other patient had modest pain reduction after two treatments.

Conclusions: This pilot study has shown the effectiveness of the *MonaLisa Touch*[®] fractional CO₂ laser treatment in patients with post-partum perineal pain.

Keywords: Perineal trauma, CO₂ fractional laser, post-partum dyspareunia, episiotomy, perineal tear.

***MonaLisa Touch*[®] Dual Probe Therapy for the Treatment of Lichen Sclerosus and Vaginal Atrophy**

J. R. Dell, M.D., FACOG¹, FACS², FPMRS³

Director, Institute for Female Pelvic Medicine. Knoxville, Tennessee - USA.

¹: Fellow of the American College of Obstetricians and Gynecologists; ²: Fellow of the American College of Surgeons; ³: Female Pelvic Medicine & Reconstructive Surgery.

Abstract

Objective: Lichen Sclerosus (LS) is a chronic, inflammatory, mucocutaneous disorder which affects both females and males. We report our clinical experience on 15 patients with LS and postmenopausal vaginal atrophy treated with *MonaLisa Touch*[®] dual probe therapy simultaneously to address both conditions.

Methods: All patients were offered dual probe therapy to simultaneously address the vaginal atrophy as well as the LS. The treatment protocol was initially 3 treatments at 40-50 days interval. At each treatment session, patients underwent treatment of the vagina with the 360° probe followed immediately at the same session with the external (vulvar) probe for affected vulvar tissue.

Results: The results revealed that the 15 patients (100%) reported improvement in their vulvar symptoms with 1 patient reporting only minimal improvement (10%) in vulvar symptoms after 3 treatments. Therefore, upon completion of 3 dual probe therapy treatments, and based on clinical improvement reported by the patients, all of them were offered the opportunity to extend their external probe treatments for LS for 2 additional treatment sessions for a total of 5 vulvar treatments. The 15 patients (100%) desired to continue their treatment for 2 additional sessions. Additional improvement gained by extension of vulvar treatments. No complications were detected in patients during the treatment sessions other than mild discomfort or burning during or shortly after the treatment session.

Discussion: Little else is known about the role of laser therapy for LS. Our case series suggests that fractional CO₂ laser therapy delivered with a dual probe approach with *MonaLisa Touch*[®] may offer a valuable addition to the treatment armamentarium of LS.

Keywords: lichen sclerosus, CO₂ fractional laser, menopause, vaginal atrophy.

Vaginal atrophy is a widespread condition in the female, especially in menopause. The genital tract is indeed particularly sensitive to the decrease in oestrogen levels and approximately half of all post-menopausal women experience symptoms that are typical of genital atrophy and deeply affect sexual function as well as quality of life. With this publication DEKA wants to present *MonaLisa Touch*®, the new and innovative laser-assisted treatment for vaginal atrophy. *MonaLisa Touch*® allows for a natural *rejuvenation* of the vaginal mucosa. The term “rejuvenation” refers to a profoundly therapeutic action, not only to a purely aesthetic effect. By restoring the pre-menopausal structure of tissues it is also possible to recover the functionality that the vaginal mucosa has lost due to the ageing process.



The Code of Excellence

DEKA M.E.L.A. s.r.l.

Via Baldanzese, 17 - 50041 Calenzano (FI) - Italy
Tel. +39 055 8874942 - Fax +39 055 8832884

www.dekalaser.com

Document Reserved for Health Professionals Only.