



WHITE PAPER
SmartXide² V²LR

**Use of CO₂ Laser Therapy Against
Vaginal Atrophy, Vaginal Laxity and Urinary Incontinence.**

MonaLisa TouchTM



The Code of Excellence

Use of CO₂ Laser Therapy Against Vaginal Atrophy, Vaginal Laxity and Urinary Incontinence.

Dr. Stefano Salvatore⁽¹⁾, Prof. A. Calligaro⁽²⁾

(1): San Raffaele Hospital in Milan, Italy.

(2): University of Pavia, Italy.

From June 2012 to May 2013, there was much focus at the San Raffaele Hospital in Milan on fractional CO₂ laser treatment, using the **SmartXide² system in V²LR** mode to treat vaginal atrophy (*MonaLisa TouchTM* treatment).

According to inclusion criteria set for the study, the selection of patients depended on the following characteristics and/or symptoms:

- Post-menopausal women who have not been administered oestrogens in the 6 months prior to the beginning of the study;
- Symptoms and discomfort related to vaginal laxity, with a pelvic organ prolapse with a $\leq I$ gradient, according to the POP-Q (Pelvic Organ Prolapse Quantification system) designed by the ICS (International Continence Society);
- Vaginal dryness;
- Irritation or burning pain;
- Dyspareunia.

The exclusion criteria were as follows:

- Patients with a $\geq II$ degree of pelvic organ prolapse (ICS POP-Q grading system);
- Patients with acute or recurrent infections of the urinary tract, or genital infections (genital herpes, candidiasis);
- Patients with clinically relevant systemic disorders that can interfere with the study;
- Patients who have undergone pelvic reconstructive surgery;
- Patients who are not able to understand and follow the instructions and procedures set out for this study.

In concrete terms, a cycle of three treatments of the vaginal walls was performed using the **fractional CO₂ laser**, by

introducing probes designed for this specific purpose, on women of menopausal age with overt atrophy. The work, carried out at the Department of Gynaecology at the San Raffaele Hospital, consisted in recruitment, follow-up, and collection of data after each of the four scheduled medical examinations and two interim analyses, one in September 2012 and one in May 2013.

The two interim assessments enabled us to verify the clinical safety and efficacy of the method we had developed, in terms of the parameters to use, compared to the ex-vivo study completed last year. The study protocol involved a total of 50 patients with symptoms of genital atrophy.

- **In the first assessment**, we verified any issues concerning the tolerability of the procedure, any complications or side effects. In terms of efficacy, we analysed the changes in mean values in analogue view for all vaginal atrophy-related disorders at time 0 (recruitment) and 30-40 days after the first treatment. The analysis was then performed on 34 women recruited from our Menopause Outpatient Facility (San Raffaele Hospital in Milan, Italy) who for various reasons did not want to or could not take local oestrogen treatment. The average age of the population was 67.4 years and the follow-up was performed at a mean of 5.3 weeks from treatment. Below we report the changes in mean values on the 10-point visual analogue scale (VAS) for the various symptoms of vaginal atrophy:

- VAS for the symptom of vaginal laxity (11 patients): from 8.3 to 3.8
- VAS for the symptom of vaginal dryness (34 patients): from 8.9 to 2.3
- VAS for the symptoms of vaginal itching or burning (31 patients): from 7.8 to 2.7
- VAS for the symptom of dyspareunia (23 patients): from 8.5 to 3.1

We found no side effects or complications, though we were unable to perform the procedure on one (Asian) patient, as her vaginal size was unsuitable for the probe used in the procedure.

In this first phase, we also provided Prof. A. Calligaro (Histology and Embryology Unit of the University of Pavia, Italy) with vaginal biopsies performed on five patients before treatment and at 30-40 days after the first treatment, for histological evaluation.

- **In the second assessment (May 2013)**, we again verified any issues concerning the tolerability of the procedure, and any complications or side effects. We had no further cases of inability to perform the procedure, but in two patients we had to lower the laser power (to 24 W) because, due to their extreme vaginal atrophy, treatment proved to be uncomfortable and/or painful. Recruitment has finished and, in fact, we have even more patients under assessment than we had initially been offered. By mid-May, the patient's follow-up situation was as follows:

- 1st medical examination: 28 patients
- 2nd medical examination: 28 patients
- 3rd medical examination: 24 patients
- 4th medical examination (study completed): 20 patients

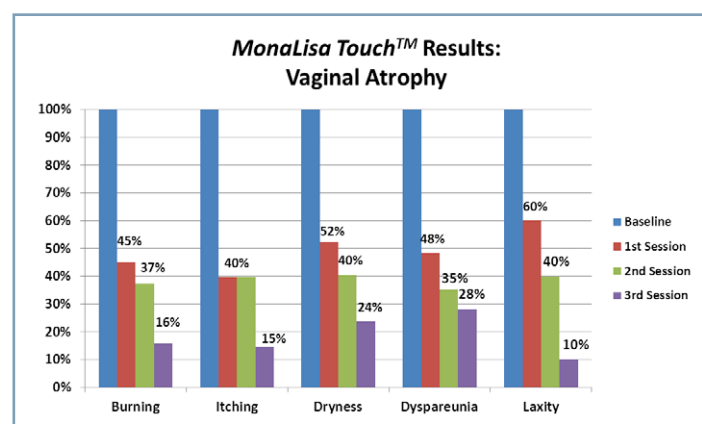
As regards the objective evaluation, we analysed the variation in the average values for the overall Vaginal Health Index (VHI) score. The analysis does not include changes in vaginal acidity (pH), as the litmus test systems proved to be inadequate to the task. Mean values for the VHI score in patients who completed the study changed as follows: 8.6, 12.4, 14.5 and 14.5 again, respectively at baseline and after each of the three individual treatments. Even though this figure is an underestimate, it testifies to the trophic changes in the vaginal canal in the patients treated.

The table 1 shows the changes in average values for the symptoms of vaginal atrophy at baseline and after each of the three individual treatments.

The table 2 shows the changes in average values for urinary symptoms at baseline and after three treatments.

	Baseline	After 1 Session	After 2 Sessions	After 3 Sessions
Vaginal Burning	5.1	2.3	1.9	0.8
Vaginal Itching	4.8	1.9	1.9	0.7
Vaginal Dryness	8.4	4.4	3.4	2
Dyspareunia	8.5	4.1	3	2.4
Vaginal Laxity	1	0.6	0.4	0.1

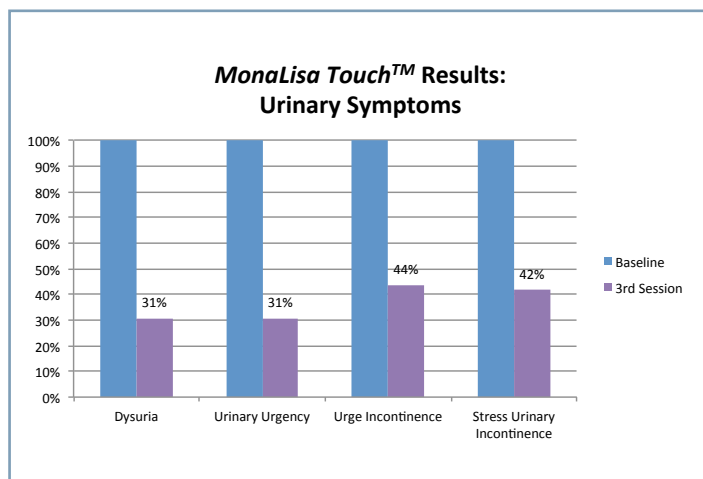
Table 1: Average VAS values for main symptoms of vaginal atrophy.



Graphic 1: Per cent representation of average VAS values for main symptoms of vaginal atrophy.

	Baseline	After 3 Sessions
Dysuria	1.3	0.4
Urinary urgency	2.6	0.8
Urge Incontinence	1.6	0.7
Stress Urinary Incontinence	3.1	1.3

Table 2: Average VAS values for main urinary symptoms, before and after 3 *MonaLisa Touch™* treatments.



Graphic 2: Per cent representation of average VAS values for main urinary symptoms, before and after 3 *MonaLisa Touch™* treatments.

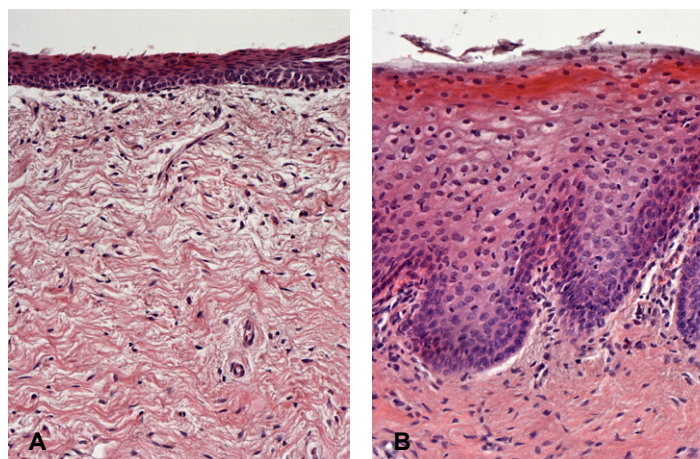


Figure 1: Histological preparation of a section of the vaginal mucosa stained with haematoxylin and eosin (H&E). (A): Vaginal mucosa in the basal condition. It is possible to see a thinner epithelium. (B): Vaginal mucosa of the same patient two months after a session with the *MonaLisa Touch™* treatment. The much thicker epithelium and shedding of numerous big cells from the free surface, together with the larger diameter of epithelial cells rich in glycogen, demonstrate the restored metabolic trophism and dynamics of the whole epithelium.



The Code of Excellence

www.dekalaser.com

DEKA M.E.L.A. s.r.l.

Via Baldanzese, 17 - 50041 Calenzano (FI) - Italy
Tel. +39 055 8874942 - Fax +39 0558832884

