

Use of the *MonaLisa Touch*[®] Treatment on Cancer Patients

Maurizio Filippini, M.D. - Miriam Farinelli, M.D.

Gynaecological Endoscopy Functional Unit of the Republic of San Marino State Hospital

Objectives: This pilot study aimed to assess the efficacy in treating atrophic vaginitis symptoms in those women who cannot receive local or systemic hormone-based therapies, since they have had a hormone-sensitive tumour.

Materials and methods: 46 treatments with the *MonaLisa Touch*[®] were performed from 01/23/2013 to 10/31/2014 at the Republic of San Marino State Hospital involved patients with neoplasias. The intensity of atrophic vaginitis symptoms was recorded for each patient.

Results: About two months after the first treatment the percent reduction of the individual symptoms was very significant, not unlike that obtained from patients who received the treatment but without neoplastic pathologies. Furthermore, after the treatment, a significant improvement in quality of life was shown.

Conclusions: Considering the absence of complications and especially the absence of contraindications, the *MonaLisa Touch*[®] laser treatment is a valuable and irreplaceable aid for all patients who cannot and prefer not to receive hormone replacement therapy.

Key words: vaginal atrophy, oestrogen-sensitive tumour, induced menopause, laser

INTRODUCTION

Vaginal atrophy, also called atrophic vaginitis, affects many women throughout the world, occurring almost always after menopause, but also in all cases where there is a lack of oestrogen, such as after childbirth, during the breastfeeding stage when ovulation is blocked or after an oestrogen-sensitive tumour (such as in the breasts, endometrium or the ovaries) where a chemotherapeutic or surgical "castration" of the menstrual cycle occurs. In these cases the use of hormone replacement therapies, even local or at low dosage, are therefore absolutely contraindicated¹.

The symptoms related to vaginal atrophy normally begin to appear between the ages of 45 and 55. Unlike other symptoms of menopause, such as the hot flashes which often decrease over time, these usually continue and can worsen as time progresses.

This condition can cause dryness, irritation, burning or pain during sexual intercourse, affecting up to 40% of postmenopausal women^{1,2}.

Until now, treatment for this condition involved the prescribing of vaginal oestrogens in the form of tablets, ovules or creams to insert into the vaginal canal using an applicator, infiltrations with substances

that have a stimulating or revitalizing action such as natural hyaluronic acid.

Borrowing from dermatological treatment for collagen stimulation which has been done for many years using CO₂ fractional laser scanning systems, scientific research has come up with a very effective therapeutic solution to improve the symptoms of vulvo-vaginal atrophy³⁻⁶.

This new therapeutic opportunity is an excellent chance for all women who suffer from these disorders, especially women who do not want to take hormones for personal or psychological reasons, believing that they are the cause of the pathology.

The importance of this treatment is all the more reason to be considered for those women who cannot receive local or systemic hormone-based therapies, since they have had a hormone-sensitive tumour^{7,8}.

MATERIALS AND METHODS

359 treatments with the *MonaLisa Touch*[®] using the CO₂ laser system SmartXide² (DEKA - Florence, Italy) were performed from 01/23/2013 to 10/31/2014 at the Republic of San Marino State Hospital; 46 of these treatments involved patients with neoplasias (36

cases of breast cancer, 4 cases of thyroid cancer, 2 cases of stomach cancer and 1 case each of intestinal cancer, ovarian cancer, endometrial cancer and lymphoma) (Fig. 1).

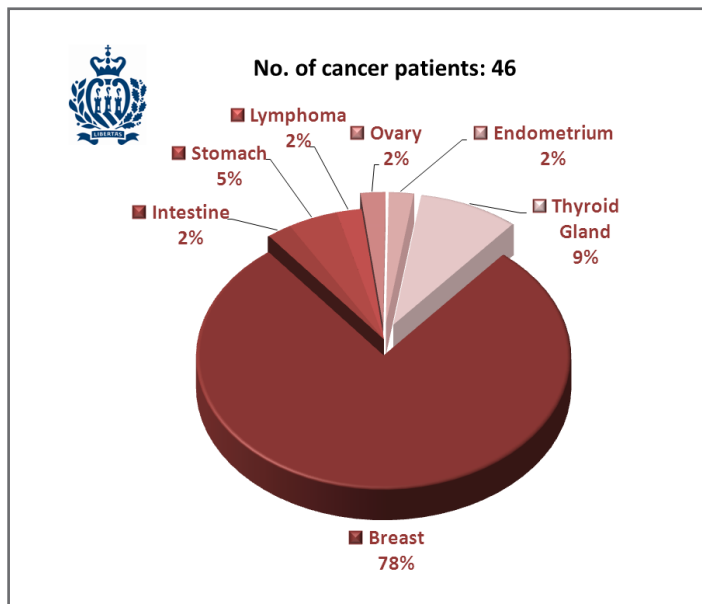


Fig. 1: Percent breakdown of the type of neoplasia in the 46 women that were treated.

All 46 patients complained of vaginal atrophy related disturbances (dyspareunia, dryness, burning, heat and vaginal itching, etc.) and were recruited through the gynaecology and oncology outpatient clinics.

Almost all cases involved patients who could not receive hormone-based therapy (especially the patients with breast or ovarian cancer) and where the therapy with moisturizing gel or pain-relief creams had little or no effect.

The intensity of all the vaginal atrophy symptoms for all patients from the Gynaecological Surgery Out-Patient Clinic of the Republic of San Marino State Hospital was quantified by means of the Visual Analogue Scale (VAS) for pain.

The *MonaLisa Touch*® treatment, done using a special CO₂ fractional laser scanning system designed especially for this type of medical application, was used over the entire vaginal epithelium (Fig. 2).

The following laser protocol was used: 40W of power, 1000 µs emission time, 1000 µm spacing and a level of SmartStack 2 (the laser beam is emitted twice on the same spot with the same energy properties), DEKA-Pulse emission mode.




Fig. 2: V²LR scanner and 360° handpiece for the *MonaLisa Touch*® treatment.

RESULTS

About two months after the first treatment the percent reduction of the individual symptoms was very significant, not unlike that obtained from patients who received the treatment but without neoplastic pathologies (Fig. 3).

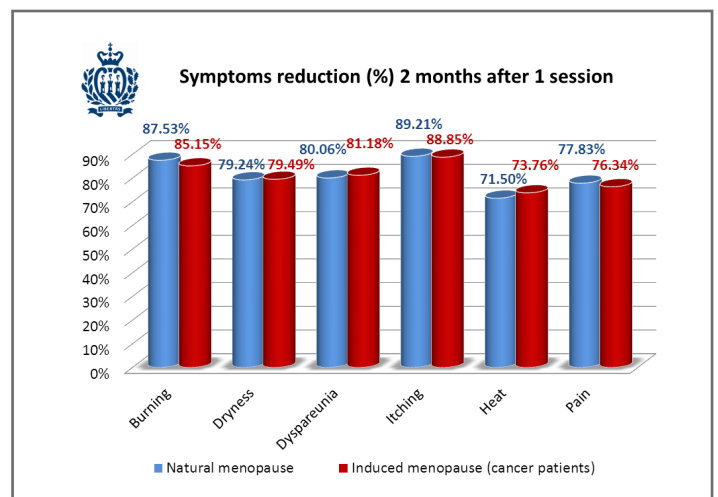


Fig. 3: Comparison of the percent reduction of the individual vaginal atrophy symptoms 2 months after the first treatment with *MonaLisa Touch*® in natural menopausal and cancer patients.

The percent reduction of the individual symptoms was 85.15% with regard to burning, 79.49% for dryness, 81.18% for dyspareunia, 88.85% for itching, 73.76% for heat and 76.34% for pain.

DISCUSSION

Thanks to the thermal effect on the vaginal structures, the heat transmitted through the laser stimulates the remodelling of the collagen and the synthesis of new collagen fibres, thus leading to functional recovery of the vagina (Fig. 4).

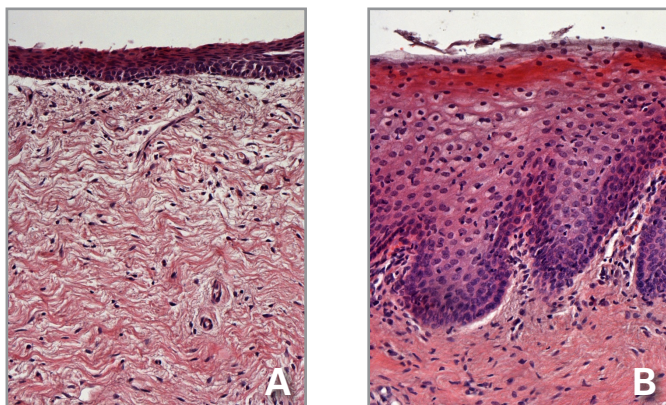


Fig. 4: Histological preparation of a section of the vaginal mucosa stained with haematoxylin and eosin (H&E). (A): Vaginal mucosa in the basal condition. It is possible to see a thinner epithelium. (B): Vaginal mucosa of the same patient two months after a session with the MonaLisa Touch® treatment. The much thicker epithelium and shedding of numerous big cells from the free surface, together with the larger diameter of epithelial cells rich in glycogen, demonstrate the restored metabolic trophism and dynamics of the whole epithelium. [Courtesy of Prof. A. Calligaro - University of Pavia, Italy]

The possibility of having heat penetrate to a controlled depth, without the use of drugs or hormones, makes this treatment not only void of side effects but also of contraindications, as even shown in the clinical studies done on ex-vivo tissue by Prof. A. Calligaro at the University of Pavia in Italy (article in press).

This aspect is so important that it makes the *MonaLisa Touch*® laser treatment nearly an irreplaceable therapy for all those patients who cannot receive local or systemic hormone-based therapies.

The mucosal tissue is treated in a soft, non-invasive manner without any bleeding, with a controlled temperature accumulation that eliminates the risk of necrosis in the surrounding tissue.

For the nature of the laser light used, this treatment is painless and non-invasive since the laser beam only penetrates a few of hundreds microns (Fig. 5).

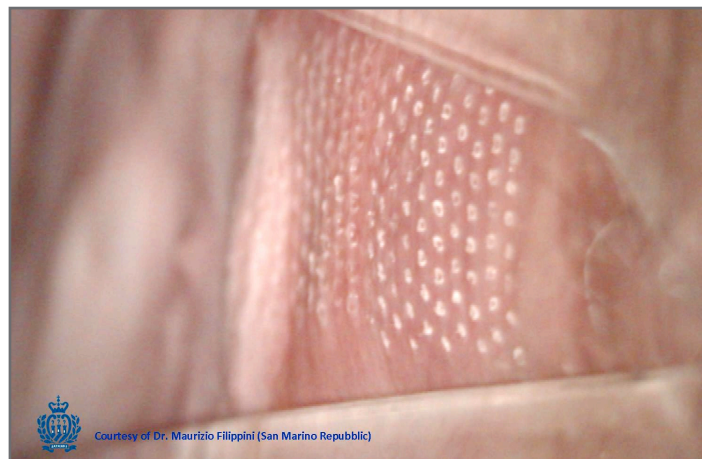


Fig. 5: Colposcopic image of the DOTs immediately after the 360° vaginal treatment.

CONCLUSIONS

Considering the absence of complications and especially the absence of contraindications, the *MonaLisa Touch*® laser treatment is a valuable and irreplaceable aid for all patients who cannot and prefer not to receive hormone replacement therapy. It is the best, if not the only, solution available by virtue of total treatment safety.

REFERENCES

1. Sturdee DW, Panay N. International Menopause Society Writing Group. Recommendations for the management of postmenopausal vaginal atrophy. *Climacteric*. 2010 Dec; 13(6): 509-22. doi: 10.3109/13697137.2010.522875. Epub 2010 Sep 30.
2. Mac Bride MB, Rhodes, Shuster LT. Vulvovaginal atrophy. *Mayo Clin Proc*. 2010 Jan; 85(1): 87-94. doi: 10.4065/mcp.2009.0413.
3. Salvatore S, Nappi RE, Zerbinati N, Calligaro A, Ferrero S, Origoni M, Candiani M, Maggiore UL. A 12-week treatment with fractional CO₂ laser for vulvovaginal atrophy: a pilot study. *Climacteric* Aug 2014, Vol. 17, No. 4: 363-369.
4. S Salvatore, U L Roberti Maggiore, M Origoni, M Parma, L Quaranta, F Sileo, A Cola, I Bainsi, S Ferrero, M Candiani, N Zerbinati. Microablative fractional CO₂ laser improves dyspareunia related to vulvovaginal atrophy: a pilot study. *Journal of Endometriosis and Pelvic Pain Disorders* 2014. DOI:10.5301/je.5000184.
5. Salvatore S, Nappi RE, Parma M, Chionna R, Lagona F, Zerbinati N, Ferrero S, Origoni M, Candiani M, Maggiore UL. Sexual function after fractional microablative CO₂ laser in women with vulvovaginal atrophy. *Climacteric* Oct 2014, 21:1-21. [Epub ahead of print].
6. P. González Isaza, A. I. Ruiz Rosas, L. Galindo. Tratamiento de la atrofía vaginal en la menopausia con microablacion con laser de CO₂ fraccionado. Un nuevo enfoque. *Revista de Enfermedades del Tracto Genital Inferior. COMEGIC*. 2014, 8(1); pp. 36-40.



7. Casey PM, Faubion SS, MacLaughlin KL, Long ME, Pruthi S. Caring for the breast cancer survivor's health and well-being. *World J Clin Oncol*. 2014 Oct 10; 5(4): 693-704. doi: 10.5306/wjco.v5.i4.693.
8. Hickey M, Saunders C, Partridge A., Santoro N, Joffe H, Stearns V. Practical clinical guidelines for assessing and managing menopausal symptoms after breast cancer. *Ann Oncol* (2008) 19 (10): 1669-1680. doi: 10.1093/annonc/mdn353 First published online: June 2, 2008.